

## PRIMARY BREAST LYMPHOMA: A CASE REPORT

HAFEEZ T<sup>1\*</sup>, ATTA MB<sup>2</sup>, IMTIAZ K<sup>3</sup>, AQEEL S<sup>2</sup>, AHMED M<sup>4</sup>, ASHRAF A<sup>4</sup>, RUBEET A<sup>4</sup>, RANDHAWA I<sup>5</sup>

<sup>1</sup>Department of Medicine, Bahria International Hospital, Lahore, Pakistan

<sup>2</sup>Department of Radiology and Breast Diagnostics, Bahria International Hospital, Lahore, Pakistan

<sup>3</sup>Department of Emergency, Bahria International Hospital, Lahore, Pakistan

<sup>4</sup>Research Coordinator, Bahria International Hospital, Lahore, Pakistan

<sup>5</sup>Department of Oncology, Bahria International Hospital, Lahore, Pakistan

\*Correspondence author email address: [tayyabaabidhafeez@live.com](mailto:tayyabaabidhafeez@live.com)

(Received, 07<sup>th</sup> May 2024, Revised 10<sup>th</sup> June 2024, Published 30<sup>th</sup> June 2024)

**Abstract:** Hematological malignancies, such as lymphomas, rarely involve breast tissues, comprising only 0.04% to 0.7% of all breast neoplasms. This rarity may be attributed to the scarcity of lymphoid tissue in the breast. Primary breast lymphomas pose a diagnostic challenge due to nonspecific imaging findings that can overlap with other breast tumors. This article provides a case study and literature review on primary breast lymphoma.

**Keywords:** Primary Breast Lymphoma, Hematological Malignancies, Breast Neoplasms, Radiography

### Introduction

Breast lymphomas are a rare occurrence and account for 0.04% to 0.7% of all breast neoplasms. They are divided into primary and secondary breast lymphomas. Primary Breast Lymphoma is the presence of breast lymphoma without evidence of a systemic lymphoma. Diffuse B cell lymphomas are the most common histological type of NHL involving the breast (1).

Wiseman and Liao first postulated the diagnostic criteria for primary breast lymphomas in 1972 (2, 3). It included:

- Adequate histological specimen from breast parenchyma and lymphomatous infiltrates.
- Absence of any previous breast malignancy
- Absence of any disseminated lymphoma at the time of investigations/diagnosis except ipsilateral axillary lymph nodes.

Two stages of PBL that directly affect patient morbidity and mortality are as follows; Stage 1 PBL is confined to the breast tissue only, without any involvement of axillary lymph nodes with a mortality rate of 15.4%. Stage 2 PBL spreads beyond the breast tissue and involves axillary lymph nodes with a mortality of 33.3% (4).

Clinical symptoms resemble other breast carcinomas, with the most common presentation being a painless breast lump (61% of cases) with local inflammatory signs (11%) and palpable lymph nodes (25%). In 12% of cases, it is reported on mammography without obvious symptoms (5).

Breast lymphomas are a challenge to diagnose because findings on imaging studies are nonspecific and overlap with other breast carcinomas (6). No single imaging finding is considered pathognomonic. On mammography, these appear as defined glandular tissues with irregular margins (69% -76%) and hyperdense areas (81%) without skin thickening and calcifications. On MRI, hypointense or isointense oval masses are seen on T1-weighted imaging, and hyperintense areas on T2-weighted imaging along with skin thickening and diffuse infiltration. Thus, MRI can give us an idea about the extent of multicentric and multifocal

lesions and help monitor the effectiveness of treatment and recurrence of disease, emphasizing the importance of this imaging modality in managing primary breast lymphoma. Histopathology is definitive for diagnosing PBL (1, 6, 7). There is no consensus on the best approach for the management and treatment of primary breast lymphoma. Chemotherapy is considered standard treatment and Cyclophosphamide, Doxorubicin, Vincristine, and Prednisone (CHOP) regimen is the most effective. It has been used alone or in combination with surgery, radiotherapy, and immunotherapy (9). Surgery is typically performed for diagnosis, but it is not recommended in the management of PBL as it has no proven impact on survival or recurrence risk (8).

### Clinical case

A 55-year-old female, resident of Lahore, Pakistan, presented to the Oncology clinic for the evaluation of a breast lump. On 28th July 2022, she developed fullness in her right breast, associated with mild pain and a low-grade fever. On self-examination, she felt a hard lump, which prompted her to visit the hospital.

She had a history of hypothyroidism, was euthyroid on levothyroxine, and was diagnosed with Diabetes Mellitus 2 years ago. On further inquiry, it was noted that the patient was nulliparous, and had no history of contraceptive use. She had no prior breast malignancy, and family history was unremarkable as well.

A detailed clinical examination revealed a retro-areolar mass in the right breast and ipsilateral axillary lymphadenopathy. Subsequently, a workup was initiated. Mammography of the right breast and axilla showed two radiolucent, well-defined small lesions with internal macrocalcifications with a popcorn appearance in the inner lower quadrant. Correlative ultrasound showed an infiltrating, hypoechoic, taller-than-wider lesion in the retro-areolar region measuring approximately 5.5 x 3.3 x

3.6cm (in CC x AP x Tr) not reaching the underlying chest wall muscles or causing architectural distortion. A moderate amount of surrounding edema was observed. No satellite nodule was seen. Pathological axillary lymphadenopathy was noted, with the rounded enlarged nodes having loss of hilum and increased cortical thickness, the largest measuring 27x10 mm with a cortical thickness of 6mm. A Mammogram of the left breast and axilla showed a well-defined radio-opaque lesion in the retro-areolar region with specks of internal calcification. Correlative ultrasound of the left breast showed two well-defined hypoechoic lesions, the larger one measuring 2.3x0.8cm with internal calcifications at the retro-areolar region. The other measured 0.7x0.5cm at a 2'oclock position. Few oval axillary lymph nodes were also seen with preserved fatty hilum, the largest measuring 2.1x0.6cm, with a normal cortical thickness of 0.18cm (Figure 1)

Based on these findings, the right breast was categorized as BIRADS Category IVc, and the left breast was categorized as BIRADS Category II.

A histological analysis of a Tru-cut biopsy of the right breast lump was made. A lymphoid neoplasm was revealed composed of large tumor cells arranged in sheets in a non-cohesive fashion, on a background of scattered lymphocytes. Tumor cells had rounded vesicular nuclei, conspicuous nucleoli, and an appreciable cytoplasm. Numerous mitoses were observed.

Immunohistochemical staining for CD20 was positive, and negative for CD5 and CK. On staining for Ki67 there was a proliferation index of 80%. The patient was thus diagnosed with Diffuse large B-cell Lymphoma and a bone scan and whole-body scan were done, which ruled out the possibility of disseminated disease.

The patient started on the CHOP regimen of chemotherapy. She completed 8 cycles, 2 weeks apart, with regular follow-ups with her oncologist, and achieved clinical and radiological responses to the therapy. She is now undergoing consolidation radiation therapy.

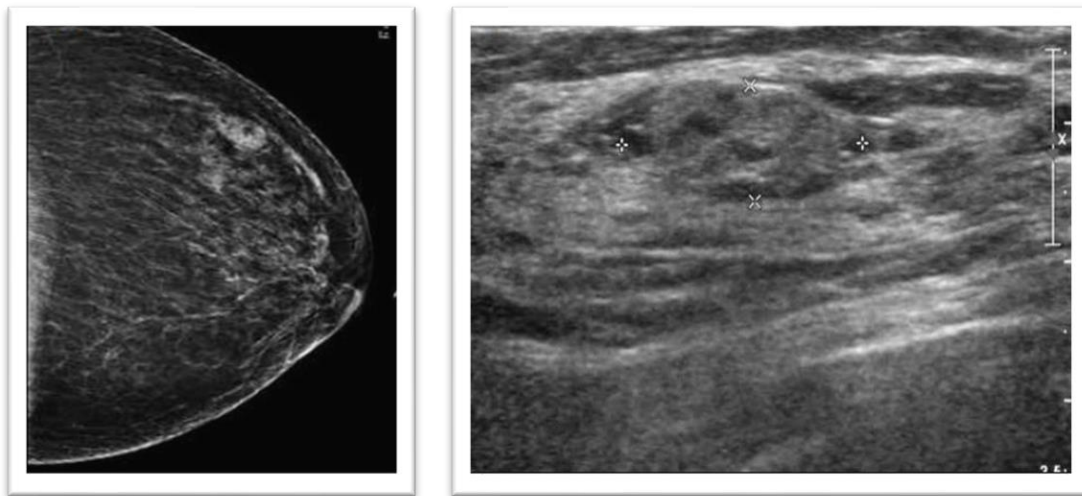


Figure 1: Memogram and USG of breast tissue

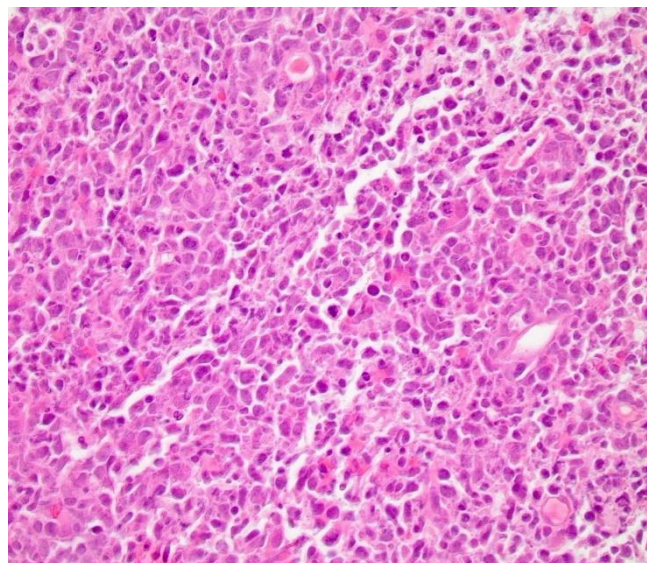


Figure 2: Histopathological slide viewed under a microscope, stained with Hematoxylin and Eosin (H&E)

## Case discussion

This patient presented with a palpable mass in her right breast. She had nonspecific findings in radiographic studies and an accurate diagnosis was established histologically (Figure 2). Although primary breast lymphoma is a rare presentation of non-Hodgkin lymphoma, it should be considered in the differential diagnoses of a breast mass. To date, there is no consensus regarding the best approach for the management of primary breast lymphoma. Chemotherapy is considered the mainstay of treatment and our patient had a positive clinical and radiological response to her treatment. Consolidation radiation therapy was started and this will be followed by a whole-body PET-CT scan to assess disease status. Surgery is not routinely performed for primary breast lymphoma as it is a hematological malignancy, however, it may be employed for diagnostic purposes.

In conclusion, clinicians should consider the possibility of primary breast lymphoma when evaluating a breast mass. Accurate diagnosis is necessary because the approach to treatment for primary breast lymphoma differs from that of breast carcinoma and other breast pathologies.

## Declarations

### Data Availability statement

All data generated or analyzed during the study are included in the manuscript.

### Ethics approval and consent to participate.

Approved by the department Concerned.

### Consent for publication

Approved

### Funding

Not applicable

## Conflict of interest

The authors declared an absence of conflict of interest.

## Authors Contribution

### TAYYABA HAFEE

*Drafting, Final Approval of version*

**MUHAMMAD BURHAN ATTA, KHADIJA IMTIAZ,**

**SHAHPER AQEEL**

*Revisiting Critically*

**MUHAMMAD AHMED, ALEENA ASHRAF, AHMAD**

**RUBEET**

*Write up, literature review*

**IMTIAZ RANDHAWA**

*Drafting*

## References

1. Walker MR. Leveraging the Cancer Stem Cell Glycome to Identify Aggressive Tumor Populations in Breast Cancer 2021.
2. Neri A, Caruso S, Cerullo G, Lenoci MP, Marrelli D, Roviello F. Primary non-Hodgkin's breast lymphoma: Surgical approach. *Cases Journal*. 2008;1:1-5.

3. Ingole S, Joseph LD, Dev B, Gnanavel H. Haematolymphoid Neoplasms of Breast. *Holistic Approach to Breast Disease*: Springer; 2023. p. 315-23.
4. Wang K, Li Z, Chen X, Zhang J, Xiong Y, Zhong G, et al. Risk of hematologic malignancies after breast ductal carcinoma in situ treatment with ionizing radiation. *NPJ Breast Cancer*. 2021;7(1):21.
5. Yoneyama K, Nakagawa M, Hara A. Primary lymphoma of the breast: A case report and review of the literature. *Radiology Case Reports*. 2021;16(1):55-61.
6. Picasso R, Tagliafico A, Calabrese M, Martinoli C, Pistoia F, Rossi A, et al. Primary and secondary breast lymphoma: focus on epidemiology and imaging features. *Pathology & Oncology Research*. 2020;26:1483-8.
7. Sakhri S, Aloui M, Bouhani M, Bouaziz H, Kamoun S, Slimene M, et al. Primary breast lymphoma: a case series and review of the literature. *Journal of Medical Case Reports*. 2023;17(1):290.
8. Hammood ZD, Salih AM, Latif S, Abdullah HO, Ali RK, Kakamad FH. Primary diffuse B-cell non-Hodgkin's breast lymphoma; A case report with a brief literature review. *Annals of Medicine and Surgery*. 2022;75.



**Open Access** This article is licensed under a Creative Commons Attribution 4.0 International License, which permits use, sharing, adaptation, distribution and reproduction in any medium or format, as long as you give appropriate credit to the original author(s) and the source, provide a link to the Creative Commons licence, and indicate if changes were made. The images or other third party material in this article are included in the article's Creative Commons licence, unless indicated otherwise in a credit line to the material. If material is not included in the article's Creative Commons licence and your intended use is not permitted by statutory regulation or exceeds the permitted use, you will need to obtain permission directly from the copyright holder. To view a copy of this licence, visit <http://creativecommons.org/licenses/by/4.0/>. © The Author(s) 2024