

## VISUAL OUTCOME FOLLOWING PARS PLANA VITRECTOMY IN POST-OPERATIVE ENDOPTHALMITIS PATIENTS

KUNDI AK, SHAHNAM T\*, AHMAD OU, RAUF S

Department of Ophthalmology, Hayatabad Medical Complex, Peshawar, Pakistan

\*Corresponding author's email address: [tariqshahnam@yahoo.com](mailto:tariqshahnam@yahoo.com)

(Received, 10<sup>th</sup> March 2024, Revised 26<sup>th</sup> April 2024, Published 8<sup>th</sup> May 2024)

**Abstract:** Postoperative endophthalmitis is a serious complication following ocular surgery that can lead to significant visual impairment. Pars plana vitrectomy (PPV) is one of the treatment options for managing this condition, but its visual outcomes are not well-established. **Objective:** This study aimed to assess the visual outcome following pars plana vitrectomy in patients with postoperative endophthalmitis. **Methods:** This interventional study was conducted at the eye ward of Hayatabad Medical Complex, Peshawar, from September 2023 to February 2024. Forty patients with postoperative endophthalmitis underwent pars plana vitrectomy. Visual acuity was evaluated in the 12th week after the procedure. **Results:** Among the patients evaluated, 15% demonstrated a visual acuity improvement of 6/18 or higher, while 22.5% showed an improvement of 6/60 or better. Additionally, 35% of patients could count fingers, 17.5% had vision of hand movement, and 10% showed no increase in visual acuity. There was no significant relationship between age distribution and post-follow-up improvement in visual acuity. **Conclusion:** Pars plana vitrectomy in patients with postoperative endophthalmitis can lead to positive outcomes in terms of improved visual acuity.

**Keywords:** Endophthalmitis, Pars Plana Vitrectomy, Visual Acuity

### Introduction

Endophthalmitis is the inflammation of the inner layers of the eye. This inflammation occurs when infectious organisms invade the inside of the eye and cause a buildup of fluid in the vitreous and aqueous fluids (1, 2). Endophthalmitis is a critical condition in ophthalmology that necessitates immediate medical intervention and treatment to preserve vision and maintain the eye's integrity. Bacteria are the primary etiological agents of endophthalmitis, with fungi being the second most prevalent cause and parasites being less frequently implicated (3). The presence of bacteria and their toxins triggers an inflammatory response that results in rapid and irreversible harm to photoreceptors and other cells in the retina (4, 5). Two distinct forms of endophthalmitis can be distinguished based on how the bacteria enter the eye: exogenous and endogenous. Exogenous endophthalmitis can be classified as post-operative endophthalmitis or post-traumatic endophthalmitis, depending on the cause. Postoperative endophthalmitis is the most prevalent type of endophthalmitis (5, 6). The incidence of endophthalmitis in Pakistan ranges from 5.1% to 7.5% (6). The prevalence of postoperative endophthalmitis, as proven by culture, was 10.88%, marking the highest recorded rate globally (7). According to a study, 127 patients were included, and one affected eye with endophthalmitis. The prevalent microorganisms responsible were Streptococcus (21.4%), followed by coagulase-negative Staphylococcus (14.5%), Aspergillus (6.9%), and Bacillus cereus (5.3%). Around 90% of cases of post-operative endophthalmitis occur following cataract surgery, which is the most prevalent type of intraocular surgery (8). The main focus of treatment is to identify the causative organism, as around 30% of patients

with postoperative endophthalmitis do not have positive culture results in (9). Collecting aqueous or vitreous fluid samples at the initial visit nine is necessary for diagnostic procedures such as gram staining, culture, and polymerase chain reaction analysis. However, intravitreal antibiotics and systemic therapy have been commonly used to treat endophthalmitis (10). As a result, more aggressive interventions may be required to restore vision and protect the eye. Initially created for managing vitreoretinal diseases, Vitrectomy has become a promising additional treatment for postoperative endophthalmitis (11). It provides various potential advantages, such as eliminating inflammatory waste, decreasing bacterial presence, and aiding in administering antibiotics to the affected intraocular tissues (12, 13).

Endophthalmitis, marked by intense inflammation inside the eye, presents a complex problem for doctors since it develops quickly, can cause vision loss, and has few therapeutic choices. The timing of vitrectomy in the context of postoperative endophthalmitis remains the subject of debate and ongoing investigation. However, due to a lack of local literature on this subject, the rationale of this study is to visualise the outcome following pars plana vitrectomy in post-operative endophthalmitis patients at our hospital setup.

### Methodology

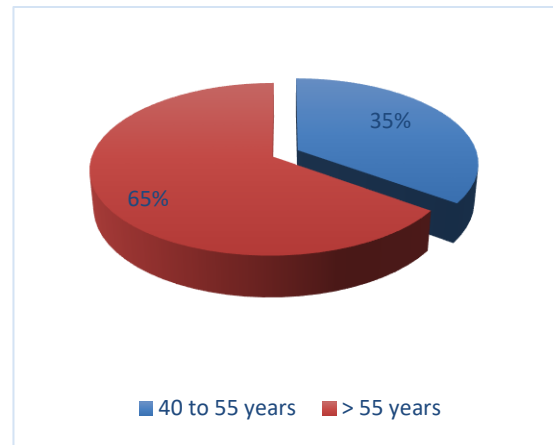
Forty patients were selected for this interventional study conducted in the eye ward of Hayatabad Medical Complex, Peshawar, Pakistan, from September 2023 to February 2024 after obtaining ethical clearance from the hospital. The study comprised patients with clinically confirmed acute

[Citation: Kundi, A.K., Shahnam, T., Ahmad, O.U., Rauf, S. (2024). Visual outcome following pars plana vitrectomy in post-operative endophthalmitis patients. *Biol. Clin. Sci. Res. J.*, 2024: 831. doi: <https://doi.org/10.54112/bcsrj.v2024i1.831>]

postoperative endophthalmitis following cataract surgery with visual acuity of light perception on the scan. Patients with endogenous or traumatic other endophthalmitis were not included in the study. Vancomycin and amikacin intravitreal injections were given together with a standard 3-port pars plana vitrectomy. Post-operatively, the patients were evaluated in the 12<sup>th</sup> week following PPV. Snellen charts were used to measure visual acuity during these exams. Additional examinations included a fundus examination and a thorough slit lamp. SPSS 23 was used to analyse the collected data. Chi-Square test was deployed for the association, keeping the value of P significant at < 0.05.

**Results**

The mean age in our study was 58.30±10 years. The mean duration between surgery and PPV was 9.23±2.90 days. The frequency of patients > 55 years old was higher than those aged 40 to 55. The frequency of male patients was 21 (52.5%), while that of female patients was 19 (47.5%). Duration of presentation was ≤ 5 days in 25 (52.5%) patients while > 5 days in 15 (37.5%) patients. The post-follow-up VA improvement was 6/18 or better in 5 (15%) patients and 6/60 or better in 9 (22.5%) patients; we observed that 14 (35%) could count their fingers, hand movement visibility was 7 (17.5%) while 4 (10%) patients showed no improvement in visual acuity. Post-follow-up improvement in VA was not notably linked with age distribution.



**Figure 1 Age distribution**

**Table 1 Post-follow-up improvement in visual acuity.**

Post-follow-up improvement in visual acuity	Frequency	Percent
6/18 or better	6	15.0
6/60 or better	9	22.5
CF	14	35.0
HM	7	17.5
No improvement	4	10.0
Total	40	100.0

**Table 2 Association of improvement in VA with age**

Parameter		Age distribution (Years)		Total	P value
		40 to 55	> 55		
Post-follow-up improvement in Visual Acuity	6/18 or better	4	2	6	0.10
		66.7%	33.3%	100.0%	
	6/60 or better	5	4	9	
		55.6%	44.4%	100.0%	
	CF	3	11	14	
		21.4%	78.6%	100.0%	
HM	2	5	7		
	28.6%	71.4%	100.0%		
No improvement	0	4	4		
	0.0%	100.0%	100.0%		
Total		14	26	40	

**Discussion**

Even though infected endophthalmitis is a relatively uncommon complication after eye surgery, it is a severe condition that has the potential to impair vision and calls for treatment that is both quick and effective (14). Surgery for cataracts is one of the surgical procedures that is performed the most frequently all over the world. It has been observed that the frequency of endophthalmitis following cataract surgery performed with contemporary phacoemulsification ranges from 0.02% to 0.08% (15).

The Endophthalmitis Vitrectomy Study (EVS) has been considered one of the most critical research investigations on the treatment of endophthalmitis ever since it was conducted in the middle of the 1990s. To create guidelines for the care of infectious endophthalmitis, the EVS consisted of a multicenter, randomised, observational clinical investigation that involved 420 consecutive

instances of endophthalmitis. The EVS was used to develop guidelines. In cases where visual acuity (VA) was higher than light perception (LP), the researchers concluded that vitrectomy did not provide any benefits (16).

Patients with endophthalmitis who appear with VAs better than LP have been doing vitrectomy procedures at an increasing rate, even though this approach violates the criteria established by the EVS. Primary vitrectomy was conducted in 41% of endophthalmitis patients in the United States between 2003 and 2004, based on information from the Medicare database. Individuals with an initial VA better than LP were eligible for the procedure (17). According to another survey conducted in Canada, most vitreoretinal surgeons in that country did not precisely adhere to the standards established by the EVS. Specifically, 56.7% of the surgeons in Canada performed primary vitrectomy on individuals suffering from endophthalmitis who had a VA of hand movement (HM) instead of managing them with

[Citation: Kundi, A.K., Shahnam, T., Ahmad, O.U., Rauf, S. (2024). Visual outcome following pars plana vitrectomy in post-operative endophthalmitis patients. *Biol. Clin. Sci. Res. J.*, 2024: 831. doi: <https://doi.org/10.54112/bcsrj.v2024i1.831>]

intravitreal antibiotics solely (36.7%). It is quite probable that this trend was influenced by the significant advancements in vitrectomy technology that have occurred since the 2000s. These advancements include sutureless small-gauge vitrectomy plus the application of a wide-viewing viewing system (18).

In our study, 40 patients who had post-procedure endophthalmitis were selected. We observed that the mean age was  $58.30 \pm 10$  years, while the mean duration between surgery and PPV was  $9.23 \pm 2.9$  days. In our study, we observed that the frequency of male patients was higher than that of female patients. A study conducted in Pakistan reported similar demographic details; the mean age they reported was  $54.50 \pm 14.14$  years, while the mean time between surgery and PPV was  $7.03 \pm 1.97$  days (19).

At post-follow-up, about 6 (15%) patients in our study had visual acuity of 6/18 or better, and nine (22.5%) had VA of 6/60 or better (14) (35%) patients could count their fingers, while 7 (17.5%) patients could view their hand movements. We observed no improvement in 4 (10%) patients. Similar to our observations, a study reported that 17.64% of patients had VA 6/18 or better post-follow-up, while 26.46% of patients had VA 6/60 or better. They noted that 9.37% of patients did not have improvement in VA (20).

### Conclusion

We conclude that PPV can improve visual acuity in post-operative endophthalmitis patients. We recommend clinical trials across multiple hospitals to further explore this outcome.

### Declarations

#### Data Availability statement

All data generated or analysed during the study are included in the manuscript.

#### Ethics approval and consent to participate

Approved by the department concerned. (HMC-IRB/10-6-23/221)

#### Consent for publication

Approved

#### Funding

Not applicable

### Conflict of interest

The authors declared the absence of a conflict of interest.

### Author Contribution

#### ARIF KHAN KUNDI

Coordination of collaborative efforts.

Conception of Study, Final approval of manuscript.

#### TARIQ SHAHNAM

Study Design, Review of Literature.

Conception of Study, Development of Research Methodology Design, Study Design, Review of manuscript, final approval of manuscript.

#### OBAID ULLAH AHMAD

Data entry and Data analysis, drafting article.

#### SHAHID RAUF

Manuscript revisions, critical input.

### References

- Dave VP, Das T. Definition, signs, and symptoms of endophthalmitis. *Endophthalmitis: A Guide to Diagnosis and Management*. 2018; 5 (2):3-8.
- Malmin A, Syre H, Ushakova A, Utheim TP, Forsaa VA. Twenty years of endophthalmitis: Incidence, aetiology and clinical outcome. *Acta Ophthalmologica*. 2021;99(1):62-9.
- Relhan N, Forster RK, Flynn Jr HW. Endophthalmitis: then and now. *American journal of ophthalmology*. 2018;187(15):93-7
- Clarke B, Williamson TH, Gini G, Gupta B. Management of bacterial postoperative endophthalmitis and the role of vitrectomy. *Survey of Ophthalmology*. 2018;63(5):677-93.
- Barry P, Cordovés L, Gardner S. ESCRS guidelines for prevention and treatment of endophthalmitis following cataract surgery: data, dilemmas and conclusions. *European Society of Cataract and Refractive Surgeons*. 2013:1-44.
- Junejo SA, Ahmed M, Alam M. Endophthalmitis in paediatric penetrating ocular injuries in Hyderabad. *J Pak Med Assoc*. 2010;60 (7): 532-5.
- Perez da Silva Pereira P, Carvalho Sabini AA, Ferreira de Almeida RM, Oliveira Pontes D, Bezerra Mororó Alves MM, Alves de Sousa V, et al. Major outbreak of endophthalmitis after cataract surgery: a retrospective cohort in northern Brazil. *Med Rxiv*, 2023.
- Yang Y, Lin L, Li Y, Jiang Z, Li C, Liu M, et al. Etiology, microbiological isolates, and antibiotic susceptibilities in culture-proven pediatric endophthalmitis: a 9-year review. *Graefes' Archive for Clinical and Experimental Ophthalmology*. 2021;259:197-204.
- Hashemian H, Mirshahi R, Khodaparast M, Jabbarvand M. Post-cataract surgery endophthalmitis: brief literature review. *J Curr Ophthalmol*. 2016;28 (3):101-5.
- Grzybowski A, Turczynowska M, Schwartz SG, Relhan N, Flynn HW. The role of systemic antimicrobials in the treatment of endophthalmitis: a review and an international perspective. *Ophthalmology and therapy*. 2020;9:485-98.
- Negretti GS, Chan W, Pavesio C, Muqit MM. Vitrectomy for endophthalmitis: 5-year study of outcomes and complications. *BMJ Open Ophthalmology*. 2020;5(1):e000423.
- Durand ML. Bacterial and fungal endophthalmitis. *Clin Microbiol Rev*. 2017;30(3):597-613.
- Ho IV, Fernandez-Sanz G, Levasseur S, Ting E, Liew G, Playfair J, et al. Early pars plana vitrectomy for treatment of acute infective endophthalmitis. *The Asia-Pacific Journal of Ophthalmology*. 2019;8(1):3-7.
- Pershing S, Lum F, Hsu S, et al. Endophthalmitis after cataract surgery in the United States: a report from the Intelligent Research in Sight Registry, 2013–2017. *Ophthalmology*. 2020;127:151–8.
- Endophthalmitis Study Group, European Society of Cataract & Refractive Surgeons Prophylaxis of postoperative endophthalmitis following cataract surgery: results of the ESCRS multicenter study and identification of risk factors. *J Cataract Refract Surg*. 2007;33:978–88.
- Results of the Endophthalmitis Vitrectomy Study A randomized trial of immediate vitrectomy and of

[Citation: Kundi, A.K., Shahnám, T., Ahmad, O.U., Rauf, S. (2024). Visual outcome following pars plana vitrectomy in post-operative endophthalmitis patients. *Biol. Clin. Sci. Res. J.*, 2024: 831. doi: <https://doi.org/10.54112/bcsrj.v2024i1.831>]

intravenous antibiotics for the treatment of postoperative bacterial endophthalmitis. Endophthalmitis Vitrectomy Study Group. Arch Ophthalmol. 1995;113:1479–96.

16. Grzybowski A, Turczynowska M, Kuhn F. The treatment of postoperative endophthalmitis: should we still follow the endophthalmitis vitrectomy study more than two decades after its publication? Acta Ophthalmol. 2018;96:e651–4.

17. Siddiqui F, Crippen C, Hutnik CM. Do we heed the endophthalmitis vitrectomy study in Canada? Can J Ophthalmol. 2002;37:395–8.

18. Soomro AR, Soomro FA, Hussain M, Soomro AQ, Qidwai N, Tariq AB. Visual Outcome in Pars Plana Vitrectomy for Acute Postoperative Endophthalmitis after Cataract Surgery. Pak J Ophthalmol. 2020 4;36(3).

19. Thapa R, Paudyal G. Clinical profile and visual outcome following pars plana vitrectomy in acute post-operative endophthalmitis. Nepal J Ophthalmol. 2011;3(2):102-8.



**Open Access** This article is licensed under a Creative Commons Attribution 4.0 International License, which permits use, sharing, adaptation, distribution and reproduction in any medium or format, as long as you give appropriate credit to the original author(s) and the source, provide a link to the Creative Commons licence, and indicate if changes were made. The images or other third party material in this article are included in the article's Creative Commons licence, unless indicated otherwise in a credit line to the material. If material is not included in the article's Creative Commons licence and your intended use is not permitted by statutory regulation or exceeds the permitted use, you will need to obtain permission directly from the copyright holder. To view a copy of this licence, visit <http://creativecommons.org/licenses/by/4.0/>. © The Author(s) 2024