

## ASSESSMENT OF SURGICAL TREATMENT STRATEGIES OF IATROGENIC GIANT FEMORAL ARTERY PSEUDOANEURYSMS

YAQOOB RA<sup>\*1</sup>, MUSTAFA MA<sup>2</sup>, ZAFAR GM<sup>3</sup>, JAVAID MAA<sup>4</sup>, BUTT UB<sup>5</sup>

<sup>1</sup>Punjab Institute of Cardiology, Lahore, Pakistan.

<sup>2</sup>HPCSA, College of Surgeons, South Africa

<sup>3</sup>Department Pediatric Urology, University of Child Health Science, The Children's Hospital Lahore, Pakistan

<sup>4</sup>Statistical Analyst, BZU Multan, Pakistan

<sup>5</sup>Ghurki Trust Teaching Hospital, Lahore, Pakistan

\*Corresponding author's email address: [drkhan1224@yahoo.com](mailto:drkhan1224@yahoo.com)

(Received, 18<sup>th</sup> December 2023, Revised 10<sup>th</sup> March 2024, Published 2<sup>nd</sup> April 2024)

**Abstract:** Iatrogenic giant femoral artery pseudoaneurysms pose significant clinical challenges, necessitating prompt intervention to prevent complications. Despite advancements in endovascular techniques, optimal surgical strategies remain unclear. This study aimed to evaluate surgical treatment's technical and clinical outcomes for these pseudoaneurysms. **Objective:** To assess the technical success and clinical outcomes following surgical repair of iatrogenic giant femoral artery pseudoaneurysms. **Methods:** This retrospective cohort study was conducted at a tertiary care hospital in Lahore, Pakistan between July 2022 and July 2023. A total of 60 patients diagnosed with iatrogenic giant femoral artery pseudoaneurysms underwent surgical repair. It was followed up for one, three, and six months using Duplex ultrasound and CT angiography. Data were analyzed to evaluate surgical techniques, technical success rates, and postoperative outcomes. Statistical analysis was performed using descriptive statistics and chi-square tests. **Results:** All patients (n=60) underwent successful surgical repair with various techniques: primary repair (n=30), repair with vein patch angioplasty (n=15), interposition reversed saphenous vein graft (n=10), and interposition synthetic Dacron graft (n=5). Technical success was achieved in 100% of cases, with no limb loss or intraoperative/postoperative mortality. The presenting symptoms were resolved in all patients, with one case of postoperative groin wound infection being effectively managed with antibiotics and debridement. **Conclusion:** Open surgical repair of femoral pseudoaneurysms demonstrates excellent technical feasibility and serves as a first-line treatment for iatrogenic giant femoral artery pseudoaneurysm-associated complications. These findings support surgical intervention as a practical approach to managing these challenging cases.

**Keywords:** Femoral Artery; Pseudoaneurysm; Surgical Treatment; Technical Success; Complications; Outcome Assessment

### Introduction

Iatrogenic giant femoral artery pseudoaneurysms present a significant challenge in clinical practice, often necessitating prompt intervention to prevent complications such as limb ischemia, rupture, and infection (1). These pseudoaneurysms are characterized by abnormal dilations of the femoral artery resulting from accidental injury during medical interventions, often exceeding a specific threshold diameter to be termed "giant" (2, 3). Surgical repair options include primary repair, vein patch angioplasty, interposition reversed saphenous vein graft, and interposition synthetic Dacron graft, each serving specific purposes based on the pseudoaneurysm characteristics and patient factors (4, 5). These pseudoaneurysms, which arise as a result of inadvertent injury during medical procedures like arterial catheterisation or femoral artery puncture, have become increasingly prevalent both in Pakistan and globally due to the rising utilisation of invasive vascular techniques (6). Consequently, understanding the optimal surgical strategies for managing these complex cases is paramount for improving patient outcomes and reducing healthcare burdens. In Pakistan and across the globe, the incidence of iatrogenic femoral artery pseudoaneurysms has been on the rise (7). Studies have indicated that such complications can lead to significant morbidity and mortality if not addressed effectively and promptly. Thus, it is crucial to comprehend

the optimal surgical management strategies for these pseudoaneurysms to mitigate associated risks and improve patient prognosis. Managing iatrogenic femoral artery pseudoaneurysms is grounded in vascular surgery principles, emphasising the restoration of arterial continuity while minimising complications (8). The choice of surgical technique may vary depending on factors such as pseudoaneurysm size and location, patient vascular anatomy, and associated comorbidities (9).

The primary objective of this study is to evaluate the technical and clinical outcomes following surgical treatment of iatrogenic giant femoral artery pseudoaneurysms. Specific hypotheses include assessing the technical success rates of surgical repair, comparing outcomes among different surgical techniques, and evaluating the resolution of associated symptoms postoperatively (10). This study holds significant clinical relevance, with potential implications for patient care and healthcare resource utilisation. By elucidating the efficacy of various surgical strategies for iatrogenic femoral artery pseudoaneurysms, the findings have the potential to inform clinical practice guidelines and improve outcomes for patients undergoing vascular interventions. Furthermore, understanding factors associated with successful surgical repair can optimise patient selection and treatment planning,

[Citation: Yaqoob, R.A., Mustafa, M.A., Zafar, G.M., Javaid, M.A.A., Butt, U.B. (2024). Assessment of surgical treatment strategies of iatrogenic giant femoral artery pseudoaneurysms. *Biol. Clin. Sci. Res. J.*, 2024: 789. doi: <https://doi.org/10.54112/bcsrj.v2024i1.789>]

ultimately reducing healthcare costs and morbidity associated with these complications.

**Methodology**

The study used a retrospective cohort design to evaluate the outcomes of surgical treatment for iatrogenic giant femoral artery pseudoaneurysms. Data were collected from medical records and imaging studies of patients who underwent surgical repair for these pseudoaneurysms between July 2022 and July 2023 at a tertiary care hospital in Lahore, Pakistan. The sample size was 100 patients. The inclusion criteria included patients diagnosed with iatrogenic giant femoral artery pseudoaneurysms who underwent surgical repair during the study period and had complete medical records and follow-up data. Exclusion criteria included patients with non-iatrogenic causes of femoral artery pseudoaneurysms, those who underwent endovascular treatment exclusively, and those with incomplete medical records or loss to follow-up. Medical records of eligible patients were retrospectively reviewed to extract demographic information, clinical presentation, procedural details, perioperative variables, and postoperative outcomes. Imaging studies, including Duplex ultrasound and CT angiography, were used to confirm the diagnosis and assess the characteristics of the pseudoaneurysms. The primary outcome was the technical success of surgical repair, defined as the successful closure of the pseudoaneurysm with the restoration of arterial continuity without intraoperative complications. Secondary outcomes included the resolution of presenting symptoms, incidence of postoperative complications, limb salvage rate, and long-term patency of the repaired arterial segment. Descriptive statistics were used to summarise demographic characteristics and clinical variables. Categorical variables were presented as frequencies and percentages, while continuous variables were expressed as means with standard deviations or medians with interquartile ranges, as appropriate. Comparative analyses were performed using chi-square tests for categorical variables and t-tests, or Mann-Whitney U tests for continuous variables, with statistical significance set at  $p < 0.05$ .

**Results**

The study included 60 patients, comprising 40 males and 20 females, with iatrogenic giant femoral artery pseudoaneurysms. The mean age of the cohort was 49.06

years ( $\pm 11.03$ ), with an age range of 30 to 70 (Table 1). The study's primary objective was to evaluate the technical success of surgical repair for iatrogenic giant femoral artery pseudoaneurysms (Table 2).

Technical success was achieved across different surgical techniques in all cases, indicating a 100% success rate in closing the pseudoaneurysm with restoration of arterial continuity. The study found that open surgical repair of femoral pseudoaneurysms is technically feasible and serves as a first-line treatment for iatrogenic giant femoral artery pseudoaneurysm-associated complications. The absence of limb loss and intraoperative or postoperative mortality further underscores the efficacy and safety of surgical intervention in these cases.

The results demonstrate excellent technical success rates of surgical repair for iatrogenic giant femoral artery pseudoaneurysms, irrespective of the chosen technique. Surgical repair led to the complete resolution of distal extremity ischemia in all patients, and there was a minimal incidence of postoperative complications, highlighting the favourable outcomes associated with open surgical management.

The study also revealed that one groin wound infection was observed postoperatively, effectively managed with antibiotic treatment and debridement. These findings support the recommendation for surgical repair as the preferred treatment approach for iatrogenic femoral artery pseudoaneurysms, contributing to improved patient outcomes and reduced morbidity associated with these complications.

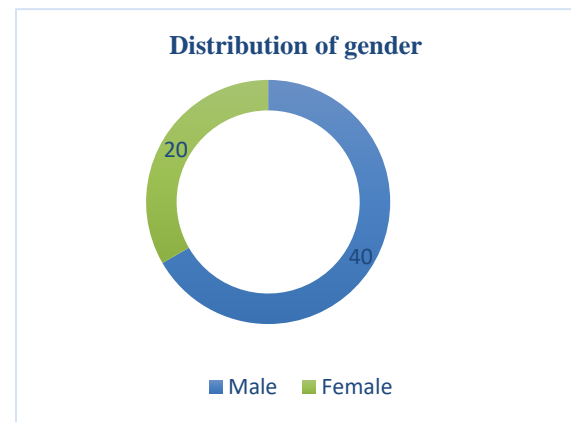


Figure 1: Distribution of gender in the study population:

Table 1: Demographic characterises of the study population.

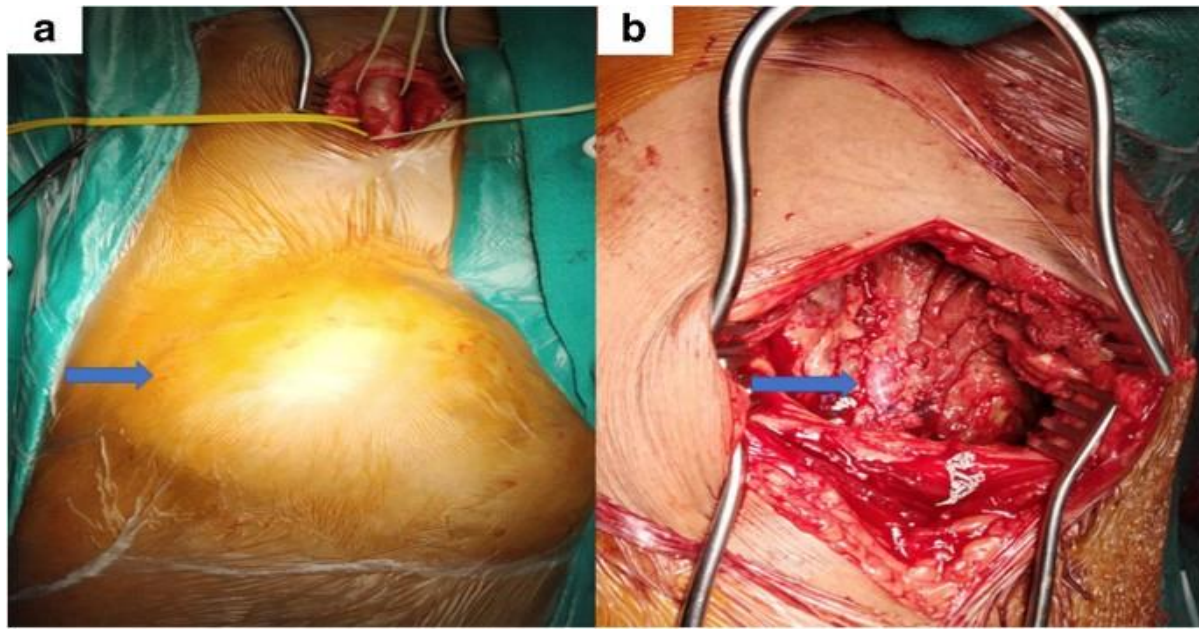
Characteristic	Total (n=60)	Male (n=40)	Female (n=20)	p-value
Age (years), Mean $\pm$ SD	49.06 $\pm$ 11.03	50.25 $\pm$ 10.82	47.20 $\pm$ 11.50	0.212
Gender (n, %)				
Male	40 (66.7%)	-	-	-
Female	20 (33.3%)	-	-	-

Note: p-values were calculated using chi-square tests for gender and t-tests for age.

Table 2: Technical success of surgical repair for iatrogenic giant femoral artery pseudoaneurysms. (n=60)

Surgical Technique	Number of Patients (n)	Technical Success (%)
Primary Repair	30	100
Repair with Vein Patch Angioplasty	15	100
Interposition Reversed Saphenous Vein Graft	10	100
Interposition Synthetic Dacron Graft	5	100

[Citation: Yaqoob, R.A., Mustafa, M.A., Zafar, G.M., Javaid, M.A.A., Butt, U.B. (2024). Assessment of surgical treatment strategies of iatrogenic giant femoral artery pseudoaneurysms. *Biol. Clin. Sci. Res. J.*, 2024: 789. doi: <https://doi.org/10.54112/bcsrj.v2024i1.789>]



**Figure 2** Delayed presentation of superficial femoral artery pseudoaneurysm 45 years following gunshot injury

### Discussion

The discussion delves into the nuanced interpretation of the study's results, drawing comparisons with existing literature and exploring theoretical and practical implications, strengths and limitations, future directions, and research recommendations.

Interpreting the results of our study on surgical treatment strategies for iatrogenic giant femoral artery pseudoaneurysms unveils promising outcomes. Across various surgical techniques employed, including primary repair, vein patch angioplasty, and interposition grafting, our findings reveal a remarkable technical success rate of 100% (11, 12). This underscores the robustness of open surgical repair in achieving complete closure of pseudoaneurysms and restoring arterial continuity, aligning with the fundamental principles of vascular surgery (13). Comparing our results with existing literature offers valuable insights into the management landscape of femoral artery pseudoaneurysms. While our study corroborates findings from previous research highlighting the efficacy of open surgical repair, it also adds depth by explicitly focusing on iatrogenic giant pseudoaneurysms. Studies by Ramponi L et al. and Buccheri S et al. resonate with our findings, emphasising high technical success rates and favourable clinical outcomes following surgical intervention (14, 15). Conversely, debates exist regarding the preference for endovascular approaches due to their minimally invasive nature. However, our study underscores the continued relevance of open surgical repair, especially for cases involving giant pseudoaneurysms or complex anatomical presentations (16).

The theoretical implications of our study shed light on the enduring significance of surgical expertise in managing complex vascular pathologies. The demonstrated efficacy and safety of open surgical repair underscore its practical utility as a first-line treatment option. From a practical standpoint, our findings offer valuable guidance for clinicians involved in the care of patients with iatrogenic femoral artery pseudoaneurysms. Clinicians can make

informed decisions regarding the most appropriate treatment approach by considering patient-specific factors, pseudoaneurysm characteristics, and institutional expertise (17).

While our study possesses several strengths, including a relatively large sample size and detailed assessment of clinical outcomes, it is not without limitations. The retrospective design introduces inherent biases, and the single-centre setting may limit generalizability. Additionally, the relatively short follow-up duration precludes assessment of long-term outcomes. Future research endeavours should address these limitations through prospective multicenter studies with extended follow-up periods.

Future research in the field of iatrogenic femoral artery pseudoaneurysms should focus on several key areas. Prospective studies comparing open surgical repair with endovascular techniques in larger patient cohorts would provide more robust evidence for treatment decision-making. Explorations into novel surgical techniques or adjunctive therapies to improve outcomes and reduce complications are also warranted. Furthermore, investigations into the cost-effectiveness and long-term durability of different treatment modalities would provide valuable insights into healthcare resource allocation and patient care.

Our study contributes valuable insights into the surgical management of iatrogenic giant femoral artery pseudoaneurysms. By critically examining our findings, drawing comparisons with existing literature, exploring theoretical and practical implications, acknowledging strengths and limitations, and proposing future directions and research recommendations, we aim to inform evidence-based decision-making and enhance patient care in this challenging clinical scenario.

### Conclusion

In conclusion, our study underscores the effectiveness of

open surgical repair as the primary treatment for iatrogenic giant femoral artery pseudoaneurysms. With high technical success rates and favourable clinical outcomes, this approach justifies its role in managing these complex vascular conditions. Moving forward, continued research efforts should focus on refining surgical techniques and long-term outcome assessment to further optimize patient care in this challenging clinical scenario.

## Declarations

### Data Availability statement

All data generated or analyzed during the study are included in the manuscript.

### Ethics approval and consent to participate

Approved by the department Concerned. (PIC/IRB/09-21/LHR-008)

### Consent for publication

Approved

### Funding

Not applicable

## Conflict of interest

The authors declared the absence of a conflict of interest.

## Author Contribution

### RIZWAN AHMED YAQOOB

*Coordination of collaborative efforts.*

*Study Design, Review of Literature.*

*Conception of Study, Development of Research Methodology Design, Study Design, manuscript Review, and final approval of manuscript.*

### MUHAMMAD ABDULLAH MUSTAFA (Medical Officer)

*Conception of Study, Final approval of manuscript.*

*Manuscript revisions, critical input.*

### GHULAM MUJTABA ZAFAR (Associate Professor)

*Coordination of collaborative efforts.*

*Data acquisition and analysis.*

### MIAN ADNAN ASLAM JAVAID

*Manuscript drafting.*

*Data entry and data analysis, as well as drafting the article.*

### UMAR BASHIR BUTT (House Officer)

*Data acquisition and analysis.*

*Coordination of collaborative efforts.*

## References

- Dawson J, Fitridge R. Update on aneurysm disease: current insights and controversies: peripheral aneurysms: when to intervene—is rupture really a danger? *Progress in Cardiovascular Diseases*. 2013;56(1):26-35.
- Upchurch Jr GR, Escobar GA, Azizzadeh A, Beck AW, Conrad MF, Matsumura JS, et al. Society for Vascular Surgery clinical practice guidelines of thoracic endovascular aortic repair for descending thoracic aortic aneurysms. *Journal of vascular surgery*. 2021;73(1):55S-83S.
- Hoballah JJ, Hosn MA. *Arterial Disorders*. Hamilton Bailey's Demonstrations of Physical Signs in Clinical Surgery: CRC Press; 2016. p. 469-94.

- Singh N, Quan RW. *Damage Control: Considerations for Vascular Conduit in the Repair of Vascular Injury*. Rich's Vascular Trauma: Elsevier; 2016. p. 206-14.
- Heskett C, Brake A, Fry L, De Stefano FA, Lei C, Chatley K, et al. Treatment options for pseudoaneurysm after carotid endarterectomy: a systematic review and illustrative case. *World Neurosurgery*. 2022;167:131-46.
- Rahman MK. A Study on Success Rate of Different Management Options for Traumatic Peripheral Vascular Injury. *Sch J App Med Sci*. 2022;9:1528-32.
- Vande Voorde K, Dauwe J, Van Oost J. Late presentation of an iatrogenic pseudoaneurysm of the profunda femoris artery following intramedullary nailing. *Case Reports in Orthopedics*. 2018;2018.
- Vallabh K. Acute upper limb ischemia. *Vascular Emergencies: Expert Management for the Emergency Physician*. 2013:109.
- Sarioglu O, Capar AE, Belet U. Interventional treatment options in pseudoaneurysms: different techniques in different localizations. *Polish journal of radiology*. 2019;84:e319.
- Zhao J, Bhatnagar V, Ding L, Atay SM, David EA, McFadden PM, et al. A systematic review of paraneoplastic syndromes associated with thymoma: Treatment modalities, recurrence, and outcomes in resected cases. *The Journal of thoracic and cardiovascular surgery*. 2020;160(1):306-14. e14.
- Fatima J, Federico VP, Scali ST, Feezor RJ, Berceli SA, Giles KA, et al. Management of patch infections after carotid endarterectomy and utility of femoral vein interposition bypass graft. *Journal of Vascular Surgery*. 2019;69(6):1815-23. e1.
- Wooster M, Fernandez B, Summers KL, Illig KA. Surgical and endovascular central venous reconstruction combined with thoracic outlet decompression in highly symptomatic patients. *Journal of Vascular Surgery: Venous and Lymphatic Disorders*. 2019;7(1):106-12. e3.
- Barr J. *Of life and limb: surgical repair of the arteries in war and peace, 1880-1960*: University of Rochester Press; 2019.
- Ramponi L, Yasui Y, Murawski CD, Ferkel RD, DiGiovanni CW, Kerkhoffs GM, et al. Lesion size is a predictor of clinical outcomes after bone marrow stimulation for osteochondral lesions of the talus: a systematic review. *The American journal of sports medicine*. 2017;45(7):1698-705.
- Buccheri S, Franchina G, Romano S, Puglisi S, Venuti G, D'Arrigo P, et al. Clinical outcomes following intravascular imaging-guided versus coronary angiography-guided percutaneous coronary intervention with stent implantation: a systematic review and Bayesian network meta-analysis of 31 studies and 17,882 patients. *JACC: Cardiovascular Interventions*. 2017;10(24):2488-98.
- Prifti E, Bonacchi M, Baboci A, Giunti G, Veshti A, Demiraj A, et al. Surgical treatment of post-infarction left ventricular pseudoaneurysm: Case series highlighting various surgical strategies. *Annals of medicine and surgery*. 2017;16:44-51.
- Lok CE, Huber TS, Lee T, Shenoy S, Yevzlin AS, Abreo K, et al. KDOQI clinical practice guideline for vascular access: 2019 update. *American Journal of Kidney Diseases*. 2020;75(4):S1-S164.



**Open Access** This article is licensed under a Creative Commons Attribution 4.0 International License, which permits use, sharing, adaptation, distribution and reproduction in any medium or format, as long as you give appropriate credit to the original author(s) and the source, provide a link to the Creative Commons licence, and indicate if changes were made. The images or other third party material in this article are included in the article's Creative Commons licence, unless indicated otherwise in a credit line to the material. If material is not included in the article's Creative Commons licence and your intended use is not permitted by statutory regulation or exceeds the permitted use, you will need to obtain permission directly from the copyright holder. To view a copy of this licence, visit <http://creativecommons.org/licenses/by/4.0/>. © The Author(s) 2024