

CONJUNCTIVITIS INFECTION: A BRIEF REVIEW ON ITS CLASSIFICATION, ETIOLOGY AND THERAPEUTIC INTERVENTIONS

ZULFIQAR M¹, RAFIQUE S², HABIB A³, QADER A^{*4}, ASGHAR A⁵, RIAZ R⁵

¹College of Pharmacy, Lyallpur Institute of Advanced Studies (LIAS), Faisalabad Pakistan

²Department of Pharmacy, The University of Faisalabad, Faisalabad, Pakistan

³Medina College of Pharmacy, The University of Faisalabad, Faisalabad Pakistan

⁴Department of Pharmaceutical Chemistry Government College University Faisalabad, Pakistan/Primary and Secondary Health Care Department, Government of Punjab Pakistan

⁵Riphah Institute of Pharmaceutical Sciences, Riphah International University Faisalabad Campus, Pakistan

*Corresponding author email address: pharmacistqader316@gmail.com

(Received, 19th December 2023, Revised 09th March 2024, Published 17th April 2024)

Abstract: Conjunctivitis is a common inflammatory disease in humans, and it has different types of categories, such as acute, chronic, infectious, and noninfectious. Conjunctivitis may break as an epidemic in different areas of the world. It causes discomfort in the eyes. Some signs and symptoms like redness of the eye, eye discharge, grittiness of the eyes, and lashes sticking together may appear. Based on etiologic agents, conjunctivitis is classified as viral conjunctivitis, bacterial conjunctivitis, allergic conjunctivitis, follicular conjunctivitis, and neonatal conjunctivitis. It may be due to contact with people having eye infections. Many strains of bacteria, viruses, and allergens cause different types of conjunctivitis. Many treatment strategies are applied to treat various kinds of conjunctivitis worldwide. Usually, antibiotics are used for the treatment of conjunctivitis, such as ophthalmic ointments erythromycin, chloramphenicol, and fusidic acid treatment. As a home remedy, many people wash their eyes with normal saline and water to reduce the duration of eye diseases.

Keywords: Conjunctivitis, Categories, Treatment, Antibiotics

Introduction

Any membrane inflammation that covers the exposed sclera and lines the eyelids is called conjunctivitis. Conjunctivitis is the most frequent reason for "red eye" (1). The hallmarks of conjunctivitis are blood vessel engorgement, ocular discharge, discomfort, and inflammation of the conjunctiva tissue. Globally, conjunctivitis affects many people and is the most common cause of clinical visits to general medicine and ophthalmology specialists. Non-ophthalmologists, such as internists, family medicine doctors, pediatricians, and nurse practitioners, are reported to diagnose more than 80% of all acute instances of conjunctivitis annually (2). Between 2% and 3% of all visits to the emergency rooms and general care are related to eye

issues. Acute angle-closure glaucoma, orbital cellulitis, and herpetic keratitis are some of the most dangerous eye conditions that can produce eye pain. Common conditions that can cause eye pain include conjunctivitis, corneal abrasions, and hordeolum (3). The conjunctiva has bulbar and palpebral sections, which are thin, transparent, and somewhat elastic tissue layers. The conjunctiva's palpebral component covers the inside of the eyelids, while the bulbar section lines the outside of the globe. The episclera, sclera, and uveal tissue layers are beneath the conjunctiva (4). The current study highlights some critical aspects of conjunctivitis infection accompanying its classification and etiological and therapeutic intervention aspects.

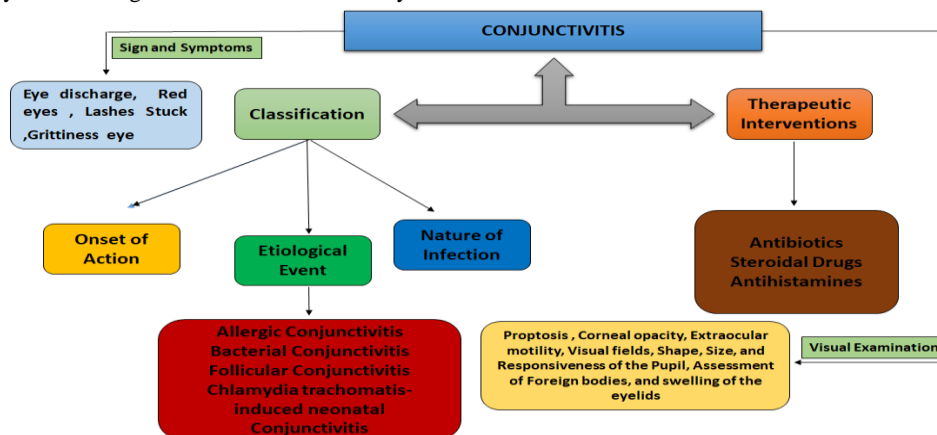


Figure 1: The schematic representation explaining the classification and therapeutic interventions of conjunctivitis

Classification based on onset of infection

It may manifest as chronic or acute. In contrast to chronic conjunctivitis, defined as lasting longer than four weeks, acute conjunctivitis refers to symptoms that appear and remain for three to four weeks, usually lasting only one or two weeks.

Classification of the base nature of infection

Conjunctivitis can be classified as infectious or non-infectious (5, 6). When faced with acute infectious conjunctivitis, most general practitioners believe they cannot distinguish between a viral or bacterial etiology. Antibiotics are given to more than 80% of these individuals (7, 8). About 80% of cases of infectious conjunctivitis are caused by viral infection, with bacterial infections following closely after.

Noncontagious classification

The forms that are not contagious include those that are immune-mediated, neoplastic, allergic, and mechanical/irritating /toxic. The allergic conjunctivitis is the most prevalent, impacting about 40% of people in the US. Based on the clinical response's severity and how it first manifested, conjunctivitis can also be categorized as acute, chronic, or recurrent (9, 10).

Classification based on etiologic agents**Allergic conjunctivitis**

A set of conditions known as allergic conjunctivitis is brought on by the body's reaction to allergens in the surroundings. While allergic conjunctivitis often does not impair vision, it can cause considerable symptoms and decrease a patient's quality of life. This is especially true for children and teenagers, who are more susceptible to certain diseases (11, 12). The phrase "allergic conjunctivitis" is broad, and it includes vernal keratoconjunctivitis (VKC), Atopic keratoconjunctivitis (AKC), and Seasonal allergic conjunctivitis (SAC), Perennial allergic conjunctivitis (PAC) (13). The only ocular condition that exclusively involves a type I allergic reaction is allergic conjunctivitis (AC) (14). There are two further types of AC. Seasonal allergic conjunctivitis and perennial allergic conjunctivitis, the former being more prevalent. The type of allergen patients are sensitive to determines whether the symptoms are periodic or chronic. Seasonal allergens are Tranquility allergens, like grass or tree pollen, that cause seasonal problems. Perennial allergens include House dust mites, animal dander, mold spores, cockroaches, and rats, which are examples of indoor allergens that induce perennial symptoms (15, 16, 17). Among conjunctivitis cases, 53–73 percent are caused by bacteria.

Bacterial conjunctivitis

Inflammation of the conjunctiva brought on by a bacterial infection is known as bacterial conjunctivitis. Direct contact with contaminated fluids can result in conjunctival irritation or bacterial conjunctivitis. The etiology of bacterial conjunctivitis is Staphylococcus species, S. pneumonia, H. influenza, and M. catarrhalis. These are the most prevalent organisms. It manifests as crusty eyelids, mucopurulent discharge, and conjunctival injection. Most of the time, the diagnosis is clinical. Although there is strong evidence that antibiotics increase the remission rate, the illness frequently resolves independently. The majority of available data indicates that the treatment plan and the choice of topical antibiotics do not substantially impact the rate of infection

recovery (18). Although estimates vary wildly, bacterial conjunctivitis is less common in adults than viral conjunctivitis. Adult cases of bacterial conjunctivitis are most frequently caused by Staphylococcus species, followed in frequency by Haemophilus influenza and Streptococcus pneumonia. Bacterial conjunctivitis is primarily caused by H influenza, S. pneumonia, and Moraxella. Catarrhalis is more common in children than viral conjunctivitis (19). Since it was first identified several centuries ago, newborn/neonatal conjunctivitis has been known to be one of the most prevalent illnesses during the first month of life. It continues to be a significant cause of ocular morbidity, which is highly concerning to public health, particularly in poor nations (20).

Chlamydia trachomatis-induced neonatal conjunctivitis

Chlamydia trachomatis-induced neonatal conjunctivitis is an acute conjunctival infection characterized by palpebral conjunctivae, purulent eye discharge, erythema, and edema of the eyelids. It usually appears five to fourteen days after delivery but may appear sooner (21). The incidence of conjunctivitis in infants is influenced by the frequency of infections in the mother, preventative measures and conditions during childbirth, and exposure to microbes after delivery (22).

Follicular conjunctivitis

Conjunctival hyperemia and lymphoid follicle growth on the eyelid's conjunctiva are the hallmarks of follicular conjunctivitis, which produces irritation and inflamed eyes, frequently lasting for many weeks (23). There was evidence of adenovirus serotype 4a-induced follicular conjunctivitis. The clinical symptoms persisted for a long time (11±5 days) (24).

Etiology of conjunctivitis

Various infectious agents can cause conjunctivitis but can also be linked to immune-related conditions, nutritional deficiencies (particularly vitamin A), and congenital metabolic syndromes (porphyria and Richner-Hanhart syndrome). Immune-related disorders include Reiter syndrome, Stevens-Johnson syndrome, keratoconjunctivitis sicca, and others (25, 26). For patients suffering from ocular infections, this has meant that the etiologic agent or etiology must be identified quickly and that the correct antibiotic treatment must be started right once. Conjunctivitis is a prevalent ocular condition affecting people of all ages in Nigeria. In 1971, a conjunctivitis outbreak was reported in Nigeria (27).

Between 2006 and 2008, 85 bacterial strains originating from conjunctival elevates were identified in the Craiova Emergency Clinical Hospital lab. Using contemporary techniques for bacteria, the strains that have been identified and isolated are Escherichia coli, Haemophilus influenza, peptostreptococcus, and Staphylococcus aureus. The above-mentioned strains of different bacteria were the most frequently isolated species. Every bacterial species had a distinct level of drug sensitivity. As demonstrated by our research, Gram-positive bacteria played a significant role in the etiology of infections, with Gram-negative bacteria coming in second (28). All across the world, adenoviruses can infect various vertebrate hosts. They are non-enveloped, medium-sized (90–100 nm), double-stranded DNA viruses. Since they were discovered in 1953, at least 57 different adenovirus serotypes and seven adenoviral species (A–G)

have been found in humans. The human adenoviruses (HAdVs) have some subtypes like subgroup B, and these subgroups cause the following diseases: Pharyngoconjunctival fever (PCF), Epidemic

keratoconjunctivitis (EKC), acute hemorrhagic conjunctivitis (AHC) is among the ocular illnesses primarily caused by subgroups B and D (29).

Table 1: Representing the different types of conjunctivitis, its causative agent, and susceptible population.

Sr.	Types of conjunctivitis	Causative agent	Susceptible population	References
1	Infectious Conjunctivitis	Viruses and Bacteria	Children	32
2	Non-contagious Conjunctivitis	Immune system Neoplastic& other mechanical or toxic cause	Adults	18
3	Allergic Conjunctivitis	Allergens like pollen, dust, mites, and mold spores.	Children and teenagers	44
4	Bacterial Conjunctivitis	S.Pneumonia, H.Influenza, M.catarrhils	Rare in adults and expected in children	11
5	Follicular Conjunctivitis	Adenovirus-serotype 4a	Adults	15

Treatment of conjunctivitis

In the pediatric clinic of the Amir Kabir Hospital in Arak, Iran, a randomized clinical trial was conducted for the treatment of conjunctivitis. Two therapy groups were randomly assigned to 110 newborns, who were given either brewed black tea plus 1% ophthalmic erythromycin ointment with sulfacetamide drop 10% (group A)TDS or only group B antibiotics for seven days. Before administering medicines, group A members cleansed their sticky eyelids with sterile cotton soaked in brewed black tea, while the control group only received antibiotic administration. The length of the illness and the severity of the conjunctivitis at the first, third, and seventh days of treatment were assessed. Antibiotics added to brewed black tea lessened the intensity and length of treatment for infants' conjunctivitis. For adjusting treatment, it appears to be secure, efficient, affordable, and readily available (30).

The approaches taken for treatment differ significantly among nations. Primary care is where the majority of patients are initially treated. Here, they receive "wait-and-see" lubrication and antiseptic or antibacterial treatment. Most general practitioners (GPs) in Europe prescribe broad-spectrum topical antibacterials when they prescribe antibacterials. First-line fluoroquinolone treatment is unusual; general practitioners typically recommend fusidic acid and chloramphenicol. Topical antibacterials are often utilized at the specialist (ophthalmologist) level or as a second-line treatment at the general practitioner level. But topical fluoroquinolones, especially the ones that the European Medicines Agency recently approved, such as topical levofloxacin and topical moxifloxacin, are rarely used and are only used as a last option in most countries. Besifloxacin, gatifloxacin, and lomefloxacin topical medications are also available in various parts of the world (31).

Even when over-the-counter (OTC) drugs are ineffective, patients frequently self-medicate with them and neglect to seek professional assistance. In one study, the first course of action for 56% of patients diagnosed with AC was self-treatment. The most popular treatment was to wash the eyes with saline or water. Many over-the-counter medications (OTC) have limited effectiveness for AC, e.g., topical vasoconstrictors, and can have unfavorable side effects (e.g., oral antihistamines can cause mucosal dryness or sleepiness; topical vasoconstrictors can cause rebound

vasodilation) (32, 33). Ophthalmic steroid drops work well to treat AC, but long-term steroid therapy carries risks that an optometrist or ophthalmologist should closely monitor and monitor. These risks include elevated intraocular pressure, cataract development, central serous chorioretinopathy, and less common issues like ptosis, mydriasis, and skin thinning of the eyelids when using skin applications (34,35,36).

Topical moxifloxacin has a long residence duration, high potency, and mean concentration in conjunctival tissue, which makes it possible to use a three-times-daily dosage schedule for five days. Moreover, topical moxifloxacin is the first ocular antibiotic in Europe to be offered as a multidose, self-preserved topical solution, reducing the possibility of allergic reactions and swelling associated with the benzalkonium chloride preservative. Furthermore, topical moxifloxacin is well tolerated by patients and has a pH of 6.8, which is almost neutral (37). Individuals suffering from allergic conjunctivitis have ten times higher levels of histamine in their tears. The histamine H1 antagonist levocabastine was recently produced and is available as a nasal spray and eye drops. Levocabastine was discovered to be the most effective antihistaminic substance on the market, 15,000 times more active than chlorpheniramine, in well-established tests of antihistamine activity. According to research on human ocular provocation, levocabastine shields against the signs and symptoms of allergen-induced conjunctivitis (38). For those suffering from allergic conjunctivitis, levocabastine looks to be a beneficial treatment (39). Nowadays, acyclovir, trifluridine, and valaciclovir are frequently utilized as antiviral medications to treat infections caused by herpes viruses. Adenoviral conjunctivitis has occasionally been successfully treated with cidofovir; however, toxicity has also been documented. Because of their high toxicity, the usage of other drugs, such as idoxuridine, has been reduced in clinical practice (40). There isn't a proven treatment for other viral causes of conjunctivitis. Thus, care is mainly focused on symptomatic management (41).

Signs and symptoms of conjunctivitis

Infectious conjunctivitis can be diagnosed in part by looking for sure clinical signs and symptoms, such as Eye discharge, red eyes, lashes stuck together in the morning, grittiness in the eye(s), edema of the eyelid or conjunctiva, a history of coming into touch with people who had conjunctivitis (42).

[Citation: Zulfiqar, M., Rafique, S., Habib, A., Qader, A., Asghar, A., Riaz, R. (2024). Conjunctivitis infection: a brief review on its classification, etiology and therapeutic interventions. *Biol. Clin. Sci. Res. J.*, 2024: 780. doi: <https://doi.org/10.54112/bcsrj.v2024i1.780>]

Patient's ocular history and physical examination

As is naturally the case, a history and physical examination are crucial for diagnosing and treating conjunctivitis. Time of onset, prodromal symptoms, unilateral or bilateral eye involvement, associated symptoms, prior treatment and response, past episodes, type of discharge, presence of pain, itching, features of the eyelids, periorbital involvement, changes in vision, photophobia, and corneal opacity are essential considerations when taking the patient's ocular history.

The main goal of the ocular examination should be to evaluate conditions like proptosis (protrusion of eyeball), corneal opacity, extraocular motility, visual fields, discharge type, shape, size, and responsiveness of the pupil, tonometry, assessment of foreign bodies, and swelling of the eyelids. Conjunctivitis usually causes diffuse redness of the conjunctiva. More severe disorders like keratitis, iritis, and angle-closure glaucoma include the entire bulbar (43).

When need to visit an eye specialist

Cases with visual loss, moderate to severe pain, significant purulent discharge, or any corneal involvement should be sent immediately to an ophthalmologist or other eye care specialist (44,45). Among the eye disorders that clinicians see most frequently is ocular allergies. Since it is impossible to identify a single cause for its increase, specialists are examining the potential roles of many factors, such as early childhood exposure, urban air pollution, and genetics (46). A common immunological inflammatory condition affecting the eye's anterior surface is ocular allergies. The International Consensus on Ocular Allergy was created to provide a general overview of ocular allergies (OA) and to identify unmet needs regarding the diagnosis and treatment of the spectrum, which includes seasonal/intermittent, perennial/persistent, vernal, and atopic kerato-conjunctivitis (47).

Conclusion

Conjunctivitis is an ocular disease affecting populations worldwide. This ocular disease is an inflammation of the conjunctiva, which is a thin transparent tissue layer. Depending upon the duration of the disease, conjunctivitis can be taken as chronic or acute. Chronic conjunctivitis lasts more than four weeks, while acute conjunctivitis lasts at least one or two weeks. It may be infectious or non-infectious. Eye discharge, red eyes, grittiness in eyes, and pain are the main signs and symptoms of conjunctivitis. There are various classes of conjunctivitis, including viral, bacterial, neonatal, and follicular conjunctivitis. The etiologic agents are staphylococcus species, S. pneumonia, H influenza, E. coli, adenovirus, and gram-positive and gram-negative strains. Each agent has a different level of drug sensitivity. Many ophthalmologists recommend 1 %ophthalmic erythromycin ointment. The first line of treatment is fluoro- quinolones. Generally, eye care specialists also recommend chloramphenicol and fusidic acid treatment. Topical dosage forms of moxifloxacin and levocabastine, a nasal spray, are also available for the treatment of conjunctivitis.

Declarations**Data Availability statement**

All data generated or analyzed during the study are included in the manuscript.

Ethics approval and consent to participate

Approved by the department concerned.

Consent for publication

Approved

Funding

Not applicable

Conflict of interest

The authors declared the absence of a conflict of interest.

Author Contribution**MALAIKA ZULFIQAR**

Coordination of collaborative efforts.

Conception of Study, Final approval of manuscript.

SADIA RAFIQUE

Manuscript revisions, critical input.

Coordination of collaborative efforts.

AAMNA HABIB

Data acquisition and analysis.

Manuscript drafting.

ABDUL QADER

Study Design, Review of Literature.

Conception of Study, Development of Research Methodology Design, Study Design, Review of manuscript, and final approval.

SADIA RAFIQUE

Coordination of collaborative efforts.

ANAM ASGHAR

Data entry and data analysis, as well as drafting the article.

Data acquisition and analysis.

References

1. BenEzra D. Current practice: diagnosis and treatment in primary healthcare. *Allergy*. 1995;50(21 Suppl):30-3
2. Shekhawat NS, Shtein RM, Blachley TS, Stein JD. Antibiotic prescription fills for acute conjunctivitis among enrollees in a large United States managed care network. *Ophthalmology* 2017;124:1099–1107.
3. pflipsen m, massaquoi m, wolf s. Evaluation of the painful eye. *I am a fam physician*. 2016;93:991–998
4. BenEzra D. Current practice: diagnosis and treatment in primary healthcare. *Allergy*. 1995;50(21 Suppl):30-3.
5. de Laet C, Dionisi-Vici C, Leonard JV, McKiernan P, Mitchell G, Monti L, de Baulny HO, Pintos-Morell G, Spiekerkötter U. Recommendations for the management of tyrosinaemia type 1. *Orphanet J Rare Dis*. 2013 Jan 11;8:8.
6. Sati A, Sangwan VS, Basu S. Porphyria: varied ocular manifestations and management. *BMJ Case Rep*. 2013 May 22;2013.

[Citation: Zulfiqar, M., Rafique, S., Habib, A., Qader, A., Asghar, A., Riaz, R. (2024). Conjunctivitis infection: a brief review on its classification, etiology and therapeutic interventions. *Biol. Clin. Sci. Res. J.*, 2024: 780. doi: <https://doi.org/10.54112/bcsrj.v2024i1.780>]

7. Sheikh A, Hurwitz B Topical antibiotics for acute bacterial conjunctivitis: a systematic review. *Br J Gen Pract* 2001; 51:473–7.
8. Everitt H, Little P. How do GPs diagnose and manage acute infective conjunctivitis? A GP survey. *Fam Pract* 2002; 19:658–60.
9. American Academy of Ophthalmology Cornea/External Disease Preferred Practice Pattern Panel. *Conjunctivitis Preferred Practice Pattern*. San Francisco, CA: American Academy of Ophthalmology; 2018. Available from <https://www.aao.org/preferred-practice-pattern/conjunctivitis-ppp-2018>. Accessed November 26, 2018.
10. Azari AA, Barney NP. Conjunctivitis: a systematic review of diagnosis and treatment. *JAMA*. 2013;310(16):1721–1729. doi:10.1001/jama.2013.28031
11. Patel N, Venkateswaran N, Wang Z, Galor A. Ocular involvement in atopic disease: a review. *Curr Opin Ophthalmol*. 2018;29:576–581.
12. Butrus S, Portela R. Ocular allergy: diagnosis and treatment. *Ophthalmol Clin North Am*. 2005;18:485–492.
13. Bielory L, Frohman L: Allergic and immunologic disorders of the eye. *J Allergy Clin Immunol*. 1992, 86: 1-20.
14. Bielory L, Frohman L: Allergic and immunologic disorders of the eye. *J Allergy Clin Immunol*. 1992, 86: 1-20.
15. Bielory L, Meltzer EO, Nichols KK, Melton R, Thomas RK, Bartlett JD. An algorithm for the management of allergic conjunctivitis. *Allergy Asthma Proc*. 2013;34(5):408–20
16. Barney N, Cook E, Stahl J. Allergic and immunologic diseases of the eye. In: Adkinson Jr N, Bochner B, Burks W, Busse W, Holgate S, editors. *Middleton's allergy: principles and practice*. 8th ed. Philadelphia: Elsevier Health Sciences; 2013. p. 618–38.
17. Bielory L. Allergic and immunologic disorders of the eye. Part II: ocular allergy. *J Allergy Clin Immunol*. 2000;106(6):1019–32.
18. Cindy Hutnik & Mohammad H Mohammad-Shahi (2010) Bacterial conjunctivitis, *Clinical Ophthalmology*, 4:, 1451-1457, DOI: 10.2147/OPTH.S10162
19. Epling J. Bacterial conjunctivitis. *BMJ Clin Evid*. 2012 Feb 20;2012:0704. PMID: 22348418; PMCID: PMC3635545
20. Abdulsalam M, Ibrahim M, Asani M O. An overview of neonatal conjunctivitis . *Sudan Med Monit* 2015;10:91-8
21. Andrew Zikic, Holger Schünemann, Teodora Wi, Ornella Lincetto, Nathalie Broutet, Nancy Santesso, Treatment of Neonatal Chlamydial Conjunctivitis: A Systematic Review and Meta-analysis, *Journal of the Pediatric Infectious Diseases Society*, Volume 7, Issue 3, September 2018, Pages e107–e115, <https://doi.org/10.1093/jpids/piy060>
22. Abdulsalam M, Ibrahim M, Asani M O. An overview of neonatal conjunctivitis . *Sudan Med Monit* 2015;10:91-8
23. <https://doi.org/10.3389/fmed.2017.00105>
24. Artieda J, Montes M, Vicente D, et al. Outbreak of follicular conjunctivitis caused by adenovirus in a geriatric centre. *Enfermedades Infecciosas y Microbiologia Clínica*. 2010 Dec;28 (10):690-693. DOI: 10.1016/j.eimc.2010.04.008. PMID: 20952102.
25. de Laet C, Dionisi-Vici C, Leonard JV, McKiernan P, Mitchell G, Monti L, de Baulny HO, Pintos-Morell G, Spiekerkötter U. Recommendations for the management of tyrosinaemia type 1. *Orphanet J Rare Dis*. 2013 Jan 11;8:8.
26. Sati A, Sangwan VS, Basu S. Porphyria: varied ocular manifestations and management. *BMJ Case Rep*. 2013 May 22;2013.
27. Iwalokun, B.A., Oluwadun, A., Akinsinde, K.A. et al. Bacteriologic and plasmid analysis of etiologic agents of conjunctivitis in Lagos, Nigeria. *J Ophthalm Inflamm Infect* 1, 95–103 (2011). <https://doi.org/10.1007/s12348-011-0024-z>
28. Therapeutics, Pharmacology & Clinical Toxicology, 2010, Vol 14, Issue 2, p103
29. ZHANG L, ZHAO N, SHA J, et al. Virology and epidemiology analyses of global adenovirus-associated conjunctivitis outbreaks, 1953–2013. *Epidemiology and Infection*. 2016;144(8):1661-1672. doi:10.1017/S0950268815003246
30. Attarha, M. Effect of Brewed Black Tea as Adjunct Treatment in Severity of Infants' Conjunctivitis. *Pediatr Res* 70 (Suppl 5), 427 (2011). <https://doi.org/10.1038/pr.2011.652>
31. Benitez-del-Castillo, J., Verboven, Y., Stroman, D. et al. The Role of Topical Moxifloxacin, a New Antibacterial in Europe, in the Treatment of Bacterial Conjunctivitis. *Clin. Drug Investig.* 31, 543–557 (2011). <https://doi.org/10.2165/11589020-000000000-00000>
32. Palmares J, Delgado L, Cidade M, Quadrado MJ, Filipe HP, Season Study Group. Allergic conjunctivitis: a national cross-sectional study of clinical characteristics and quality of life. *Eur J Ophthalmol*. 2010;20(2):257–64
33. Emanuel IA, Parker MJ, Traub O. Undertreatment of allergy: exploring the utility of sublingual immunotherapy. *Otolaryngol Head Neck Surg*. 2009;140 (5):615–21.
34. Chan LY, Adam RS, Adam DN. Localized topical steroid use and central serous retinopathy. *J Dermatolog Treat*. 2016;27(5):425–6.
35. Renfro L, Snow JS. Ocular effects of topical and systemic steroids. *Dermatol Clin*. 1992;10(3):505–12.
36. Renfro L, Snow JS. Ocular effects of topical and systemic steroids. *Dermatol Clin*. 1992;10(3):505–12.
37. Benitez-del-Castillo, J., Verboven, Y., Stroman, D. et al. The Role of Topical Moxifloxacin, a New Antibacterial in Europe, in the Treatment of Bacterial Conjunctivitis. *Clin. Drug Investig.* 31, 543–557 (2011). <https://doi.org/10.2165/11589020-000000000-00000>
38. Parys, W., Blockhuys, S. & Janssens, M. New trends in the treatment of allergic conjunctivitis. *Doc Ophthalmol* 82, 353–360 (1992). <https://doi.org/10.1007/BF00161023>
39. Parys, W., Blockhuys, S. & Janssens, M. New trends in the treatment of allergic conjunctivitis. *Doc*

[Citation: Zulfiqar, M., Rafique, S., Habib, A., Qader, A., Asghar, A., Riaz, R. (2024). Conjunctivitis infection: a brief review on its classification, etiology and therapeutic interventions. *Biol. Clin. Sci. Res. J.*, 2024: 780. doi: <https://doi.org/10.54112/bcsrj.v2024i1.780>]

- Ophthalmol 82, 353–360 (1992).
<https://doi.org/10.1007/BF00161023>
40. Skevaki, C.L., Galani, I.E., Pararas, M.V. et al. Treatment of Viral Conjunctivitis with Antiviral Drugs. *Drugs* 71, 331–347 (2011).
<https://doi.org/10.2165/11585330-000000000-00000>
41. Skevaki, C.L., Galani, I.E., Pararas, M.V. et al. Treatment of Viral Conjunctivitis with Antiviral Drugs. *Drugs* 71, 331–347 (2011).
<https://doi.org/10.2165/11585330-000000000-00000>
42. Everitt H, Little P. How do GPs diagnose and manage acute infective conjunctivitis? A GP survey. *Fam Pract* 2002;19:658–660.
43. de Laet C, Dionisi-Vici C, Leonard JV, McKiernan P, Mitchell G, Monti L, de Baulny HO, Pintos-Morell G, Spiekerkötter U. Recommendations for the management of tyrosinaemia type 1. *Orphanet J Rare Dis*. 2013 Jan 11;8:8.
44. American Academy of Ophthalmology Cornea/External Disease Preferred Practice Pattern Panel. Conjunctivitis Preferred Practice Pattern®. San Francisco, CA: American Academy of Ophthalmology; 2018. Available from <https://www.aao.org/preferred-practice-pattern/conjunctivitis-ppp-2018>. Accessed November 26, 2018.
45. Azari AA, Barney NP. Conjunctivitis: a systematic review of diagnosis and treatment. *JAMA*. 2013;310(16):1721–1729. doi:10.1001/jama.2013.280318
46. Leonardi S, del Giudice Miraglia M, La Rosa M, Bellanti JA: Atopic disease, immune system, and the environment. *Allergy Asthma Proc*. 2007, 28 (4): 410-417. 10.2500/aap.2007.28.2954.
47. Hyperosmolar conjunctival provocation for the evaluation of nonspecific hyperreactivity in healthy patients and patients with allergy *J Allergy Clin Immunol* (2006).
48. Saleem, A., Davis, M., Rafique, S., Meer, S., Qader, A., & Aslam, M. N. (2023). A Critical Glance to Non-Pharmacological Management of Novel COVID-19 Infection: Non-Pharmacological Management of COVID-19 Infection. *Pakistan Journal of Health Sciences*, 02-13.



Open Access This article is licensed under a Creative Commons Attribution 4.0 International License, which permits use, sharing, adaptation, distribution and reproduction in any medium or format, as long as you give appropriate credit to the original author(s) and the source, provide a link to the Creative Commons licence, and indicate if changes were made. The images or other third party material in this article are included in the article's Creative Commons licence, unless indicated otherwise in a credit line to the material. If material is not included in the article's Creative Commons licence and your intended use is not permitted by statutory regulation or exceeds the permitted use, you will need to obtain permission directly from the copyright holder. To view a copy of this licence, visit <http://creativecommons.org/licenses/by/4.0/>. © The Author(s) 2023

[Citation: Zulfiqar, M., Rafique, S., Habib, A., Qader, A., Asghar, A., Riaz, R. (2024). Conjunctivitis infection: a brief review on its classification, etiology and therapeutic interventions. *Biol. Clin. Sci. Res. J.*, 2024: 780. doi: <https://doi.org/10.54112/bcsrj.v2024i1.780>]