

**EFFECTIVENESS OF RADIOLOGICAL IMAGING TECHNIQUES (X-RAYS, MDCT, AND MRI) FOR DIAGNOSIS OF PELVIC FISTULA: A SYSTEMATIC REVIEW**

**SHAHZAD M<sup>1</sup>, ANJUM N<sup>2</sup>, SIRAJ S<sup>1</sup>, OMER MA\*<sup>3</sup>, SHABBIR R<sup>1</sup>, MASOOD A<sup>4</sup>**

<sup>1</sup>*Sahiwal Medical College Demonstrator Pathology Department Section Microbiology, Pakistan*

<sup>2</sup>*Radiology Department, The University of Lahore, Lahore, Pakistan*

<sup>3</sup>*Department of Radiology DHQ Hospital Sheikhpura, Pakistan*

<sup>4</sup>*WAPDA Hospital Faisalabad, Pakistan*

Corresponding author email: [dr.arслан14@gmail.com](mailto:dr.arслан14@gmail.com)

(Received, 5<sup>th</sup> December 2020, Revised 27<sup>th</sup> April 2021, Published 30<sup>th</sup> April 2021)

**Abstract:** *This study aimed to evaluate the diagnostic performance of different imaging techniques for preoperative detection of pelvic fistula. Imaging and classification of female genital abnormalities considerably pelvic floor fistulas are significant. We conducted a systematic review of the available literature to highlight the effectiveness of different radiological imaging techniques (X-RAY, U/S, CT, MRI) for the diagnosis of different types of pelvic fistulas to see the limitations of conventional scanning and testing over modern imaging techniques and to show the effectiveness of choosing one imaging modality over other depending upon multiple dynamics e.g., site and types of fistula. The controlled and regular research cases (n= 9) available in English from 2011 to 2020 were included in the criteria of research. The evidence databases were used for the assessment of certain studies analytically by way of the PEDro scale and explicated under decision guidelines. In all relevant articles were identified and included in this systematic review. The radiological techniques showed improved diagnostic performance that established the effectiveness of imaging advancement for the administration and treatment of pelvic fistula. Conventional methods have less sensitivity and specificity as compared to modern techniques. X-RAY fistulography and ultrasonography have less sensitivity and specificity as compared to CT scan but still found beneficial in the diagnosis of colovaginal, uterovesical fistula and considered as the most basic clue about the existence of a malignant fistula respectively. It is verified that MDCT is the safer accurate and offered more detailed defects in the diagnosis of urogenital, urethrorectal, lower urogenital tract fistulas, upper and middle vaginal fistulas colovesical fistulas (along with X-RAY), and prostate symphyseal fistula (along with MRI). It has been concluded that MRI can access colovesical fistulas inherited vaginal fistulas and prostate symphyseal fistulas (along with CT) more efficiently. It has been concluded that diagnostic imaging for all pelvic fistula is useful, to help physicians, particularly radiologists, in the diagnosis of pelvic fistulas. The choice of imaging technique is dependent upon multiple factors. Advanced medical imaging techniques (XRAY, MDCT MRI) are considered more recommended choices as compared to conventional imaging.*

**Keywords:** MDCT, X-Rays, CT-Scan, MRI, Gynecology, Pelvic Fistula, Diagnostics, Radiology

### Introduction

Fistula is one of the most life threatening and non-fatal complications of gynecologists which the world ever seems to panic most, yet ureteric injury comes close second (Alperin *et al.*, 2013). The term “fistula” runs from the Latin language that means “tube” or “pipe” and is referred as an abnormal linkage between mesothelial or epithelial surfaces (Warembourg *et al.*, 2017). Though an infrequent surgical problem, specialized surgeons prerequisite to be familiar with the risk factors, epidemiology, treatment, and evaluation of females with fistulae, as fistula cause acute incontinence signs in females who

develop with such challenging disease. Pelvic fistulae have been recognized all over the ages, with fistulae well-known in wrinkled Egyptian ladies (Tunitsky, Abbott, & Barber, 2012). Fistulae can develop among a diversity of pelvic structures and can occur due to diverse causes (van Ramshorst *et al.*, 2020). In the developed world, the occurrence of pelvic fistula development after hysterectomy has been reported at 0.1 per cent with vesicovaginal fistulae arising in 1 out of 500-2,000 hysterectomies. Based upon a population study of 62,379 hysterectomies, the occurrence of pelvic fistula was 1 in 6000 after vaginal hysterectomy, 1 in 1,000 after abdominal hysterectomies, and 1 in 500 with laparoscopic

[Citation: Shahzad, M., Anjum, N., Omer, M.A., Shabbir, R., Masood, A. (2021). Effectiveness of radiological imaging techniques (X-Rays, MDCT, and MRI) for diagnosis of pelvic fistula: A systematic review. *Biol. Clin. Sci. Res. J.*, 2021: 62. doi: <https://doi.org/10.54112/bcsrj.v2021i1.62>]

hysterectomy (Selvaggi and Pellino, 2015). Labour dystocia is a general cause of pelvic fistula development in underdeveloped countries with rates of occurrence within the range of 0.5 to 6.5 per 1,000 deliveries and incidence rates from 5.5 to 80.5 per 1,000 deliveries in Southern Asia and Africa (Kondo *et al.*, 2011). Due to better-quality prenatal care together with access to cesarean and supervised labor and delivery, fistulae triggered by obstructed labor are rare currently in the United States. However, pelvic fistulae still occurs after acute cesarean deliveries, perineal lacerations, peripartum hysterectomy, uterine rupture, and dilation and curettage to retained conception products (Abbott *et al.*, 2014).

The uterine ruptures in obstetrics are also rare; however 22 per cent of such cases have been related to simultaneous bladder injury that may lead infrequently towards pelvic fistulae. It accounts for about 1 to 4 percent of all genitourinary fistula, with over 90 percent of them caused by non-cancerous gynecological surgery (Abdulaziz *et al.*, 2015). Majority of the cases reported after cesarean deliveries but other causes comprise radiation, malignancy, chronic infections for example tuberculosis or intrauterine device derived ischemic necrosis. Other kinds of pelvic fistula including urethrovaginal and vesicocervical are also occasional

but have been reported after placement of cerclage (Nassar, 2011). Urethrovaginal fistula commonly occurs with the incident range of 0.9-5 per cent after surgical treatment of urethral diverticulum (Tijdink *et al.*, 2011).

Moreover, the occurrence of iatrogenic ureteral injury in the course of major gynecological surgeries is reported about 0.5-2.5 per cent with few of them subsequent in fistula development (Iwamuro *et al.*, 2018). The widely held (88 per cent) of rectovaginal fistula occur due to childbirth pain. A diversity of radiographic and examinations studies have tried to recognize precisely and effectively pelvic fistulae. Intravenous urography, barium enema, cystography, colporrhaphy, and vaginography might demonstrate the existence of appropriate organs in medium, contrast, and outside the region but the fistulous tract commonly fails to identify, partially because several fistulas are small, oblique, and tortuously oriented (VanBuren *et al.*, 2018). The multidetector computed tomography (MDCT) and computed tomography (CT) reported to be the beneficial techniques in representing a pelvic fistula; but, their drawbacks include intravenous administration contrast and extra processes such as hystero-graphy (Abou-El-Ghar *et al.*, 2012).

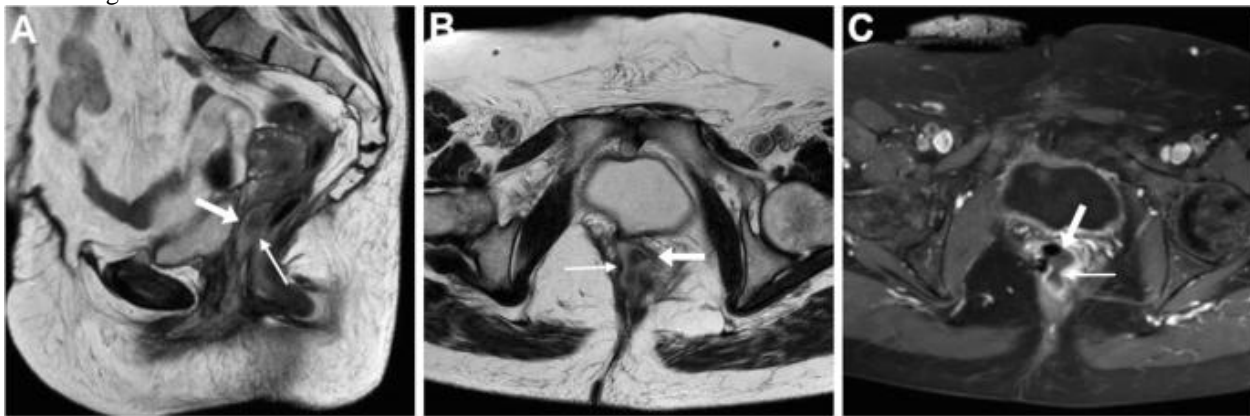

Figure 2 Pelvic and Rectovaginal Fistula on CT, MRI, and MDCT

Magnetic resonance imaging (MRI) for pelvic fistulae is a noninvasive technique which allows the prevention of iodine-based or allergic nephrotoxic contrasts and used recently in the pelvic fistula diagnostics (de Miguel *et al.*, 2012). Cystoscopy provides information regarding the urinary tract, as about 12 per cent of vesicovaginal fistulae contains an ureterovaginal fistula or concomitant ureteral injuries (Golabek *et al.*, 2013). Cystoscopic fistula imaging can evaluate the spots whether it becomes mature. The mature fistulae present smooth margins within bladder boundary while the immature fistulae

frequently have an appearance of bullous edema (Alperin *et al.*, 2013). In this systematic review, it has been planned to explain the prevailing facts required to clarify the evidence regarding the effectiveness of imaging techniques for diagnostics of pelvic fistula.

## Material and Methods

### Inclusion Criteria

Only peer reviewed research articles were included which evaluated different kinds of pelvic fistula. Participants in the trials were patients of any disease duration, of all ages, and on any form of above mentioned radiological imaging techniques. The

patients were not selected during treatment trials and reports in any other language except English.

**Literature Sources and Libraries**

For the exploitation of literature based insight studies for current research, Elsevier, Library Genesis, Wiley Online Library, Cochrane libraries, Embase, Medline, Google Scholar through PubMed in conjunction with National Library NIH of Medicine have been explored with identical keywords linked to radiological imaging techniques for diagnostics of diverse kinds of pelvic fistulas. papers have been systematically concluded to distinguish perspective approaches.

**Study Design and Interventions**

Multiple randomized, systematic and controlled procedures available in English from 2011 to 2020 were included in criteria of research. This constraint was implemented to minimize the risks of unfairness with respect to consequence assessments. The strategy to search the studies was followed by the Cochrane Movement Disorders Group that cross-referenced fundamentally as text titles and keywords including radiological imaging techniques for diagnostics of diverse kinds of pelvic fistulas.

**Data Extraction**

Entire research papers were analyzed by three independent reviewers and data extracted as stated by defined criteria resolved any inconsistencies by multiple discussions. Research papers were evaluated for methodological quality by estimating definite eligibility criteria, methods of blinding, and randomization disguise of allocation, correspondence of baseline patients in treatment groups, discrepancy in co-interventions obtained by patients all the way through the trial duration, either a purpose to treat study was conducted, or the total patients missing follow-up.

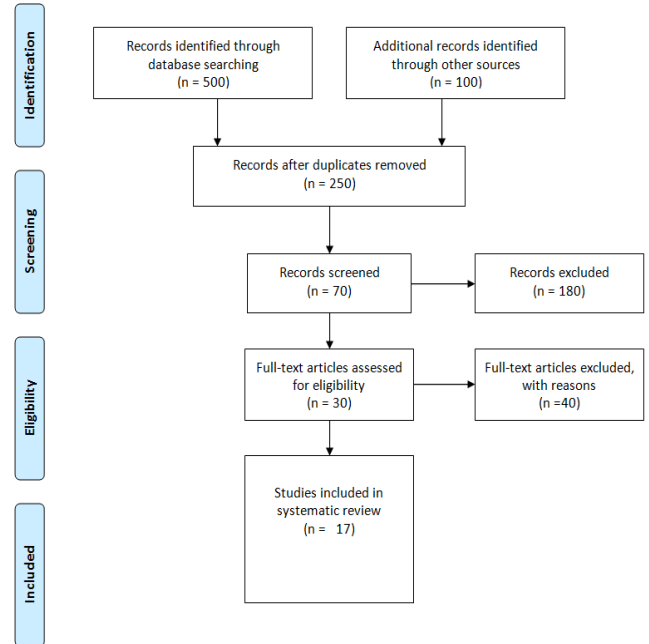
**Quality Assessment**

The Physiotherapy Evidence Database ([www.pedro.org.au](http://www.pedro.org.au)) was used for assessment of certain RCTs analytically by way of PEDro scale scores and explained under decision guidelines. Generally, the PEDro scale evaluates the practical quality of a research on the basis of imperative principles. These features make the PEDro scale a valuable instrument to evaluate the operational quality of physical therapy and therapeutic trials. The trials were individually rated and evaluated the bias risks by three authors. Studies were disqualified in the following analysis if the 5 points cut-off was not touched by PEDro scale.

**Results**

The overall 600 papers were recognized from electronic and additional searches however 250 were

duplicates. Subsequently with screening titles, abstracts, and interventions 180 studies were again skipped. The full-length texts were obtained for 30 papers of which 13 papers were removed as they did not run into inclusion criteria and thus, 17 papers included in the final qualitative research as represented by PRISMA flow diagram (Figure. 1).



**Figure.1. Prisma flowchart for selected studies**

**Table.1. Detailed information of selected studies**

Authors	Intervention	Type of Pelvic Fistula	Analysis Unit
(Tang <i>et al.</i> , 2012)	MRI	Colovesical fistula	Patients
(Botsikas <i>et al.</i> , 2012)	MDCT	Urogenital fistulas	Patients
(Sa <i>et al.</i> , 2013)	CT	Urethral-rectal fistula	Patients
(Farouk, 2014)	X-Ray	Ureterovaginal fistula	Patients
(Plateau <i>et al.</i> , 2015)	CT and MRI	Prostate symphyseal fistula	Patients
(Kamanda, 2016)	MDCT	Lower urogenital tract fistulas	Patients
(Botsikas <i>et al.</i> , 2017)	CT	Upper and middle vaginal fistulas	Patients
(Xu <i>et al.</i> , 2019)	MRI	Vaginal fistulas	Patients

[Citation: Shahzad, M., Anjum, N., Omer, M.A., Shabbir, R., Masood, A. (2021). Effectiveness of radiological imaging techniques (X-Rays, MDCT, and MRI) for diagnosis of pelvic fistula: A systematic review. *Biol. Clin. Sci. Res. J.*, 2021: 62. doi: <https://doi.org/10.54112/bcsrj.v2021i1.62>]

(Mandava *et al.*, 2020) CT and X-Ray colovesical fistula Patients

### Study Outcomes and Qualitative Analysis

Tang *et al.* (2012) reported that they selected different cases during the time period of 4 years with an ultimate clinical diagnosis of colovesical fistula with the help of MRI. The scans were revised in a consensus manner by two specialist radiologists and quantified features of MRI. The morphology of the fistula constantly came into three shapes. The most common shapes confirmed about 71 percent an intervening abscess amongst the bladder and bowel walls. The second one 15 per cent was visible track and third about 13 per cent reported whole loss of fat plane between the affected bladder and bowel. It verified the MRI as a useful imaging intervention in the pelvic fistulae diagnostics. Botsikas *et al.* (2012) performed the diagnostics of vesicovaginal and ureterovaginal fistulas with the help of 64-MDCT scanner (Sensation 64, Siemens Healthcare). Overall 3 patients were inspected and clinical symptoms involved bladder catheterization and ureteral pigtail along with urine dribbling. Consequently, it has been established that MDCT is helpful in finding the exact localization of the fistula path along with vaginal origins.

Sa *et al.* (2013) diagnosed the posterior urethral parameters related to urethrorectal fistula using computed tomography (CT) and conventional urethrography (CUG). Total 38 patients with posterior urethrorectal fistula were examined and found the accuracy in stricture location determining higher with 93.12 per cent with CT as compared to conventional CUG of 70.59 per cent. It verified that CT is safer, accurate, and offered more detailed defects as compared to orthodox urethrography. Plateau *et al.*, (2015) presented a very rare osteomyelitis pubis case in an old patient because of a prostate symphyseal fistula that developed after a few weeks of transurethral prostate resection. The patient also reported a history of prostatic carcinoma cured by radio treatment that sometimes played a part in the fistula development. CT along with excretory phase MRI were applied and made sure of the final diagnostics. It proved MRI and CT as the best imaging modalities for establishing a confident diagnosis of prostate symphyseal fistula which can also cause osteomyelitis pubis.

Kamanda, (2016) examined two cases of 29 and 51 years old females with cervix cancer and vesicovaginal fistula respectively. MDCT cystography was applied to detect the existence or nonexistence of urogenital fistulas.. The outcomes verified that MDCT cystography by means of vaginal

tampons is an inexpensive, safe, and simple technique for diagnosing the urinary fistulas. Botsikas *et al.*, (2017) explored the potential character of a CT imaging for realizing vaginal obstruction and opacification to demonstrate fistula patency. The examinations were performed on 3 patients and were technically effective as the patients revealed the presence of fistula pathways from the vaginal fornix between the necrotic cavity and vagina of a recurrent cervical cancer. It concluded CT-vaginography as an officially feasible protocol which offers functional and structural evidence about medically suspected pelvic fistula. Xu *et al.*, (2019) investigated the manifestations of MRI for inherited vaginal fistula. The clinical data and MRI findings of 12 patients were established by laparoscopy and hysteroscopic surgery and retrospectively examined. MRI mostly manifested as hemorrhage and dilatation in the cervical canal, vaginal upper part, and uterine cavity. It has been concluded that MRI can assess the kind of vaginal fistula accurately along with linked complications as well as make diagnosis efficient. Hence, it can be recommended as the effective evaluation intervention. Mandava *et al.*, (2020) tried to compare the accurateness of computed tomography (CT) and sonography for recognizing malignant fistulas. Total 35 patients were examined for complex pelvic fistula. The specificity and sensitivity of ultrasound for detection were 72 percent and 66 percent correspondingly. The outcomes recommend that though ultrasound is not the best as compared to CT as a major imaging technique to detect fistulas, it can offer the most basic clue about the existence of a malevolent fistula.

### Discussion

Imaging and classification of female genital abnormalities considerably pelvic floor fistulas are significant, however have the following fundamentals: (a) understanding of the anatomy and morphology of the female genitourinary tracts and relations with different kinds of pelvic fistulas; (b) understanding of irregularities involved in the development in addition to the resorption of pelvic fistulas (Shi *et al.*, 2018). It has reported in a previous study that diagnostic imaging for all such kinds of malformations has been presented with prominence on the more complicated abnormalities, which are better addressed on current trending technology basis (Watanabe *et al.*, 2014).

In the management of pelvic floor fistula, the recurrence is a major problem particularly in complex and persistent fistulas, which is typically because of undetected or missed infection in the course of surgical treatment (Nadir *et al.*, 2011). With the

[Citation: Shahzad, M., Anjum, N., Omer, M.A., Shabbir, R., Masood, A. (2021). Effectiveness of radiological imaging techniques (X-Rays, MDCT, and MRI) for diagnosis of pelvic fistula: A systematic review. *Biol. Clin. Sci. Res. J.*, 2021: 62. doi: <https://doi.org/10.54112/bcsrj.v2021i1.62>]

passage of time, preoperative imaging of fistulas in pelvic regions has become a regular practice to support the radiologist surgeons understand the anatomy of fistula and planning the applicable management consequently so that the probabilities of recurrence may be decreased. CT and MRI are commonly used in pelvic fistula imaging currently and so is the case with radiological fistulography (Liang *et al.*, 2013). The accuracy of X-ray fistulography in recognizing the extensions and internal opening has been found to be minimum 16 per cent with false-positive rate of 10% and hence is not considered trustworthy in appropriately diagnostics of fistula in the pelvic regions (Thabet *et al.*, 2012). However, in certain patients such as in extrasphincteric fistulas or in fistulas subsequent because of inflammatory bowel disease, fistulography has been valuable in representing the intestinal communication of fistula (Kumar *et al.*, 2012). Modified MDCT fistulography, in contrast, has been reported to be more valuable as compared to the conservative ones (Gage *et al.*, 2013).

Pelvic endosonography is a rapid, non- or minimally invasive approach that offers high-resolution pictures of the in pelvic regions and the adjacent structures and therefore may deliver the comprehensive fistula anatomy with regard to the levator plates, sphincter complex, and related potential areas (Donghai *et al.*, 2013). Another study reported 3D technology with improved diagnostics and endosonography accuracy more than 2D imaging as the precisions for primary pathways, secondary pathways, and internal overtures have enhanced from 89.4 per cent, 83.3 percent and 87.9 percent for 2D imaging to 98.5 percent 98.5 percent and 96.4 percent correspondingly, for 3D method (Brinjikji *et al.*, 2016).

### Conclusion

The recurrent and complex fistula in the pelvic region must undertake a preoperative imaging for a better sympathetic of the nature and progression of the infection to decrease the probabilities of recurrence. The choice of imaging technique is dependent upon multiple dynamics such as the characteristics of the diseases and the patients, the benefit of exclusive technology over others, surgeon's partiality, budget and accessibility of the technique, and the expertise of the radiologist. The use of conventional scanning and testing is no longer favored unless in certain situations. At the same time, MRI, MDCT and X-Ray are the recommended choices for imaging fistula in pelvic regions, computed tomography is the emerging modality that has also presented with equivalent outcomes and might be preferred because of its easier and rapid availability than usual methods.

### Conflict of interest

The authors declared absence of conflict of interest.

### References

- Abbott, S., Unger, C. A., Evans, J. M., Jallad, K., Mishra, K., Karram, M. M., ... Barber, M. D. (2014). Evaluation and management of complications from synthetic mesh after pelvic reconstructive surgery: a multicenter study. *American Journal of Obstetrics and Gynecology*, **210**(2), 163-e1.
- Abdulaziz, M., Stothers, L., Lazare, D., & Macnab, A. (2015). An integrative review and severity classification of complications related to pessary use in the treatment of female pelvic organ prolapse. *Canadian Urological Association Journal*, **9**(5–6), E400.
- Abou-El-Ghar, M. E., El-Assmy, A. M., Refaie, H. F., & El-Diasty, T. A. (2012). Radiological diagnosis of vesicouterine fistula: role of magnetic resonance imaging. *Journal of Magnetic Resonance Imaging*, **36**(2), 438–442.
- Alperin, M., Khan, A., Dubina, E., Tarnay, C., Wu, N., Pashos, C. L., & Anger, J. T. (2013). Patterns of pessary care and outcomes for medicare beneficiaries with pelvic organ prolapse. *Female Pelvic Medicine & Reconstructive Surgery*, **19**(3), 142.
- Botsikas, D., Caviezel, A., Becker, C. D., & Montet, X. (2012). A new MDCT technique for the detection and anatomical exploration of urogenital fistulas. *American Journal of Roentgenology*, **198**(2), W160–W162.
- Botsikas, D., Pluchino, N., Kalovidouri, A., Platon, A., Montet, X., Dallenbach, P., & Poletti, P.-A. (2017). CT vaginography: a new CT technique for imaging of upper and middle vaginal fistulas. *The British Journal of Radiology*, **90**(1073), 20160947.
- Brinjikji, W., Nasr, D. M., Morris, J. M., Rabinstein, A. A., & Lanzino, G. (2016). Clinical outcomes of patients with delayed diagnosis of spinal dural arteriovenous fistulas. *American Journal of Neuroradiology*, **37**(2), 380–386.
- Choi, J. M., Nguyen, V., Khavari, R., Reeves, K., Snyder, M., & Fletcher, S. G. (2012). Complex rectovaginal fistulas after pelvic organ prolapse repair with synthetic mesh: a multidisciplinary approach to evaluation and management. *Female Pelvic Medicine & Reconstructive Surgery*, **18**(6), 366–371.
- de Miguel Criado, J., del Salto, L. G., Rivas, P. F., del Hoyo, L. F. A., Velasco, L. G., de las Vacas, M. I. D. P., ... Moreno, E. F. (2012). MR imaging evaluation of perianal fistulas: spectrum of

- imaging features. *Radiographics*, **32**(1), 175–194.
- Donghai, W., Ning, Y., Peng, Z., Shuo, X., Xueen, L., Peng, Z., ... Xingang, L. (2013). The diagnosis of spinal dural arteriovenous fistulas. *Spine*, **38**(9), E546–E553.
- Farouk, K. (2014). Ureteroneocystostomy versus ureteric stenting for the management of ureterovaginal fistula. *Journal of Rawalpindi Medical College*, **18**(2), 226–229.
- Gage, K. L., Deshmukh, S., Macura, K. J., Kamel, I. R., & Zaheer, A. (2013). MRI of perianal fistulas: bridging the radiological–surgical divide. *Abdominal Imaging*, **38**(5), 1033–1042.
- Golabek, T., Szymanska, A., Szopinski, T., Bukowczan, J., Furmanek, M., Powroznik, J., & Chlosta, P. (2013). Enterovesical fistulae: aetiology, imaging, and management. *Gastroenterology Research and Practice*, 2013.
- Iwamuro, M., Hasegawa, K., Hanayama, Y., Kataoka, H., Tanaka, T., Kondo, Y., & Otsuka, F. (2018). Enterovaginal and colovesical fistulas as late complications of pelvic radiotherapy. *Journal of General and Family Medicine*, **19**(5), 166–169.
- Kamanda, M. I. (2016). MDCT cystography using vaginal tampons for imaging lower urogenital tract fistulas: two case reports. *BJR Case Reports*, 20150288.
- Kondo, W., Bourdel, N., Tamburro, S., Cavoli, D., Jardon, K., Rabischong, B., ... Canis, M. (2011). Complications after surgery for deeply infiltrating pelvic endometriosis. *BJOG: An International Journal of Obstetrics & Gynaecology*, **118**(3), 292–298.
- Kumar, A., Ahuja, C. K., Vyas, S., Kalra, N., Khandelwal, N., Chawla, Y., & Dhiman, R. K. (2012). Hepatic arteriovenous fistulae: role of interventional radiology. *Digestive Diseases and Sciences*, **57**(10), 2703–2712.
- Liang, C., Jiang, W., Zhao, B., Zhang, Y., Du, Y., & Lu, Y. (2013). CT imaging with fistulography for perianal fistula: does it really help the surgeon? *Clinical Imaging*, **37**(6), 1069–1076.
- Mandava, A., Koppula, V., Kandati, M., Sharma, G., Potlapalli, A., & Juluri, R. (2020). Ultrasound in the Diagnosis of Malignant Pelvic Fistulas: Sonographic Findings in Correlation with Computed Tomography Imaging. *Ultrasound in Medicine & Biology*, **46**(12), 3460–3467.
- Nadir, I., Ozin, Y., Kiliç, Z. M., Oğuz, D., Ulker, A., & Arda, K. (2011). Colovesical fistula as a complication of colonic diverticulosis: diagnosis with virtual colonoscopy. *The Turkish Journal of Gastroenterology: The Official Journal of Turkish Society of Gastroenterology*, **22**(1), 86.
- Nassar, O. A. H. (2011). Primary repair of rectovaginal fistulas complicating pelvic surgery by gracilis myocutaneous flap. *Gynecologic Oncology*, **121**(3), 610–614.
- Plateau, B., Ruivard, M., & Montoriol, P. (2015). Prostate Symphyseal fistula and osteomyelitis pubis following transurethral resection of the prostate: CT and MRI findings. *Journal of Medical Imaging and Radiation Oncology*, **59**(6), 713–715.
- Sa, Y. L., Xu, Y. M., Feng, C., Ye, X. X., & Song, L. J. (2013). Three-dimensional spiral computed tomographic cysto-urethrography for post-traumatic complex posterior urethral strictures associated with urethral-rectal fistula. *Journal of X-Ray Science and Technology*, **21**(1), 133–139.
- Selvaggi, F., & Pellino, G. (2015). *Pouch-related fistula and intraoperative tricks to prevent it*. Springer.
- Shi, Y., Liu, Y., Gao, F., Liu, Y., Tao, S., Li, Y., ... Guo, Q. (2018). Pancreatic stiffness quantified with MR elastography: relationship to postoperative pancreatic fistula after pancreatic enteric anastomosis. *Radiology*, **288**(2), 476–484.
- Tang, Y. Z., Booth, T. C., Swallow, D., Shahabuddin, K., Thomas, M., Hanbury, D., ... King, C. (2012). Imaging features of colovesical fistula on MRI. *The British Journal of Radiology*, **85**(1018), 1371–1375.
- Thabet, A., Kalva, S. P., Liu, B., Mueller, P. R., & Lee, S. I. (2012). Interventional radiology in pregnancy complications: indications, technique, and methods for minimizing radiation exposure. *Radiographics*, **32**(1), 255–274.
- Tijdink, M. M., Vierhout, M. E., Heesakkers, J. P., & Withagen, M. I. J. (2011). Surgical management of mesh-related complications after prior pelvic floor reconstructive surgery with mesh. *International Urogynecology Journal*, **22**(11), 1395.
- Tunitsky, E., Abbott, S., & Barber, M. D. (2012). Interrater reliability of the International Continence Society and International Urogynecological Association (ICS/IUGA) classification system for mesh-related complications. *American Journal of Obstetrics and Gynecology*, **206**(5), 442–e1.
- van Ramshorst, G. H., Young, J. M., & Solomon, M. J. (2020). Complications and Impact on Quality

- of Life of Vertical Rectus Abdominis Myocutaneous Flaps for Reconstruction in Pelvic Exenteration Surgery. *Diseases of the Colon & Rectum*, **63**(9), 1225–1233.
- VanBuren, W. M., Lightner, A. L., Kim, S. T., Sheedy, S. P., Woolever, M. C., Menias, C. O., & Fletcher, J. G. (2018). Imaging and surgical management of anorectal vaginal fistulas. *Radiographics*, **38**(5), 1385–1401.
- Warembourg, S., Labaki, M., de Tayrac, R., Costa, P., & Fatton, B. (2017). Reoperations for mesh-related complications after pelvic organ prolapse repair: 8-year experience at a tertiary referral center. *International Urogynecology Journal*, **28**(8), 1139–1151.
- Watanabe, H., Kanematsu, M., Tanaka, K., Osada, S., Tomita, H., Hara, A., ... Noda, Y. (2014). Fibrosis and postoperative fistula of the pancreas: correlation with MR imaging findings—preliminary results. *Radiology*, **270**(3), 791–799.
- Xu, S., Zhang, J., Wang, S., Yang, L., Qian, J., Yue, S., ... Yang, A. (2019). MRI features and differential diagnoses of congenital vaginal atresia. *Gynecological Endocrinology*, **35**(9), 777–781.



**Open Access** This article is licensed under a Creative Commons Attribution 4.0 International License, which permits use, sharing, adaptation, distribution and reproduction in any medium or format, as long as you give appropriate credit to the original author(s) and the source, provide a link to the Creative Commons licence, and indicate if changes were made. The images or other third party material in this article are included in the article's Creative Commons licence, unless indicated otherwise in a credit line to the material. If material is not included in the article's Creative Commons licence and your intended use is not permitted by statutory regulation or exceeds the permitted use, you will need to obtain permission directly from the copyright holder. To view a copy of this licence, visit <http://creativecommons.org/licenses/by/4.0/>.

© The Author(s) 2021