

## OUTCOMES OF ROTATIONAL ATHERECTOMY IN CALCIFIED PROXIMAL LEFT ANTERIOR DESCENDING (LAD) LESIONS IN THE CONTEXT OF TRIPLE VESSEL DISEASE

ASLAM K<sup>\*1</sup>, IQBAL E<sup>2</sup>, KHAN FR<sup>1</sup>, SAJJAD W<sup>1</sup>, KHAN MS<sup>3</sup>

<sup>1</sup>Department of Cardiology, Lady Reading Hospital, MTI Peshawar, Pakistan

<sup>2</sup>Department of Dermatology, Lady Reading Hospital, MTI Peshawar, Pakistan

<sup>3</sup>RHC Marghuz District Swabi, Pakistan

\*Corresponding author's email address: [kamran.aslam.wazir@outlook.com](mailto:kamran.aslam.wazir@outlook.com)

(Received, 15<sup>th</sup> March 2023, Revised 10<sup>th</sup> June 2023, Published 21<sup>st</sup> November 2023)

**Abstract:** Percutaneous coronary intervention (PCI) has become more complex with the advancement of medical devices. One such device is the rotational atherectomy (RA), which uses a rotating diamond-coated burr to modify calcified lesions. This makes it easier to deliver balloons and stents to specific lesions. However, there is a lack of literature regarding the success of RA in calcified proximal 'left anterior descending (LAD) lesions' following PCI. To address this gap, a study was conducted to evaluate the clinical outcomes of RA in calcified proximal LAD lesions in triple vessel disease (TVD). The study included 112 patients who underwent PCI using RA between February 2022 and November 2022 at Lady Reading Hospital, Peshawar. Data was collected using a standard report structure, including operative and follow-up details and medical and demographic features. Retrospective data was collected using medical records and interviews with patients or doctors. The ethical committee approved the study. The participants had an average age of 68.4± 0.45 years, with 85 men (75.8%) and 40 (35.7%) with diabetes mellitus. The technical success rate was 97.6%, with 20 individuals (17.8%) experiencing significant adverse cerebral and cardiac events while hospitalized. At 1.5 years, 25 (22.3%) TVFs had occurred. Independent variables such as current smoking, chronic renal disease, history of cerebrovascular attack, left ventricle ejection fraction, and left central disease were assessed to predict TVF. Based on the results, the investigation showed that rotational atherectomy in calcified proximal LAD lesions had promising success rates.

**Keywords:** Percutaneous Coronary Intervention, Rotational Atherectomy, Clinical Outcome, Left Anterior Descending Lesions, Triple- Vessel Disease

### Introduction

Percutaneous coronary intervention, or PCI, has become more often used in complex instances as device technology has advanced. Furthermore, contact with individuals presenting complicated calcifying coronary lesions in hospitals has increased in frequency due to the aging population (Okai et al., 2018). Considering this ongoing shift, the significance of techniques for altering calcified coronary lesions has escalated. These methods include the utilization of a noncompliant balloon, cut/score balloons, orbit atherectomies, intra-vascular lithotripsy, and rotational atherectomies (RA) (Barbato et al., 2015; De Maria et al., 2019; Hill et al., 2020; Lee et al., 2018).

The RA employs burr, which is of high speed and coated with diamond, to modify calcifying lesions, making it a valuable tool for plaque adjustment, ultimately facilitating the delivery of balloons and stents (Ahn et al., 1988; Tomey et al., 2014).

In day-to-day medical practices, individuals deemed suitable for RA are frequently classified as "non-option" individuals due to their concurrent health conditions. Practitioners must be vigilant regarding procedure complications and potential unfavorable clinical outcomes (Abdel-Wahab et al., 2013; Benezet et al., 2011; Jinnouchi et al., 2015; Mezilis et al., 2010; Tamekiyo et al., 2009). Given the prevalent usage of 'drug-eluting stents' (DES), along with optimal treatments like statins and intra-vascular imaging, there arises a necessity for updating results regarding the real-world clinical application of RA. Hence,

we initiated this research to scrutinize outcomes related to the procedure, events in the healthcare setup, and clinical consequences associated with RA in calcified proximal LAD lesions.

### Methodology

The study encompassed 100 patients with calcified proximal LAD lesions who underwent PCI using RA at the Lady Reading Hospital from February 2022 to November 2022. Data collection was executed through a case report form, capturing demographical and clinical characteristics and data on procedure and follow-up. Retrospective follow-up data were gathered from medical records and interviews with physicians or patients. The hospital's local ethics committee approved this investigation.

Inclusive of the study, patients from 2015 to 2019 with heavily calcified LAD lesions and significant stenosis (stenosis ≥ 75% of vessel diameter) were retrospectively enrolled from institutional databases. Two lesions identified during angiography that couldn't undergo RA were not involved in the study, 'one experienced coronary perforation' and 'cardiac tamponade before the RA procedure,' and (other encountered difficulty in passing wire in the target lesions). The chronic renal disorder was defined as a 'glomerular filtration' rate < 35% when grade III thrombolysis in MI is present.

Successful procedure was the one which was fortunate to achieve technological success and not going through 'major

[Citation: Aslam, K., Iqbal, E., Khan, F.R., Sajjad, W., Khan, M.S. (2023). Outcomes of rotational atherectomy in calcified proximal left anterior descending (LAD) lesions in the context of triple vessel disease. *Biol. Clin. Sci. Res. J.*, 2023: 603. doi: <https://doi.org/10.54112/bcsrj.v2023i1.603>]

adverse cerebral and cardiac events’ (MACCEs),’ which encompassed fatality of the individual in healthcare, cerebrovascular accidents (CVA), ‘urgent revascularization,’ MI during the procedure, or stent thrombosis during the time spent in hospital. Complications during the procedure encompass cardiac tamponades, coronary perforations, coronary dissections, pacemaker insertions (temporary), nephropathies due to contrast, and bleeding in the hospital.

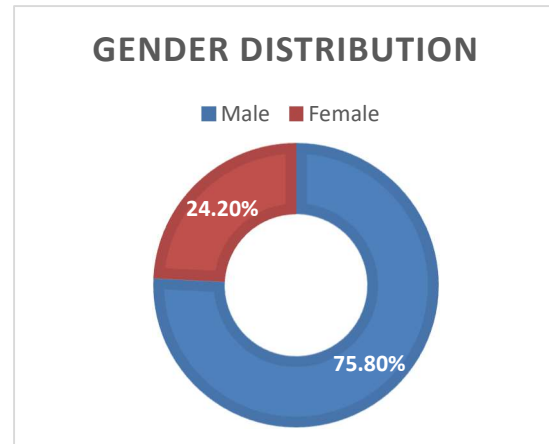
Efficiency and safety were assessed by investigating the time taken to complete the procedure, dosage of radiation, and quantity of contrast. Neuropathies due to differences after percutaneous intervention were known as kidney function impairment, in which there is a 28% increase in creatinine levels in the blood from a normal range, i.e 0.4 mg/dL, and within 42–74 hours after the procedure. All the events were confirmed by the documents in the hospital and determined independently by the doctors, who were unaware of the type of revascularization.

Statistical analyses were conducted using ‘mean ± standard deviation (SD)’ for continuous variables, compared with the ‘student t-test’ or ‘Mann–Whitney U test.’ ‘Categorical variables,’ presented as ‘counts (percentages),’ were compared using the ‘chi-square’ or ‘Fisher exact test.’ ‘Kaplan–Meier estimates’ and ‘log-rank tests’ were employed for time-to-first-event analyses. Hazard ratios (HR) for clinical outcomes were obtained through univariate Cox regression analysis, followed by a multivariate Cox proportional hazard regression model’ to identify ‘independent predictors.’ ‘All reported p-values were two-sided’. ‘P value < 0.05 was considered ‘statistically significant.’ ‘Statistical analysis’ was performed using ‘Statistical Package for Social Sciences, version 18.0.0 (SPSS Inc., Chicago, IL, USA)’.

**Results**

From February 2021 to November 2022, 112 patients who underwent ‘PCI using RA’ were included in the study. The baseline characteristics of the patients are summarized in Table 1. The mean age was 68.4 ± 0.45 years, ranging from 18 to 90 years, and the majority were male (75.8%) (Figure 1). Diabetes mellitus was present in 35.7% of patients. Above 60% of the cases had a diagnosis of acute coronary syndrome. The mean ‘left ventricular ejection fraction’ (LVEF) was 54.0 ± 12.6. ‘Dual antiplatelet therapy (DAPT)’ and statins were prescribed when individuals were discharged, i.e., 94.8% and 91.5%, respectively. ‘Values are presented as n (%) or mean ± SD.’The ‘femoral approach’ was utilized in 59.5% of cases, while the radial approach was employed in the remaining issues. Stent implantation was performed in the majority of patients (95.0%), while plain old balloon angioplasty (POBA) and drug-eluting balloon (DEB) were used in 2.0% and 2.8% of cases, respectively. The technical failure resulted in no intervention in 1.5% of patients. Intra-vascular U/S or ‘optical coherence tomography’ was utilized in 47.0% of cases. The burr which was used frequently was ‘1.5 mm’ (54.8%), following ‘1.25 mm’, ‘1.75 mm’, ‘2.0 mm’, and ‘2.5 mm’ (27.7%, 16.3%, 1.4%, and 0.4%). The ‘technical and procedural success rates’ were 97.5% and 89.2%, respectively. The average time of the procedure was 64.5 minutes, with a contrast volume of 220 ml and a radiation dose of 2695 mGy.

‘Major adverse cerebral and cardiac events (MACCEs)’ occurred in the hospital in 13.3% of individuals, and MI during the procedure in 4.46% of individuals. Death and cerebrovascular accidents (CVA) in hospitals occurred in 9.8% and 1.7% of individuals, respectively. Severe ‘coronary dissection’ and ‘coronary perforation’ occurred in 7.14% and 3.5% of individuals, respectively. Interventions that required cardiac tamponade occurred in 1.78% of individuals.



**Figure 1: Gender distribution of the study population**

**Table 1: Baseline Characteristics of Patients Undergoing PCI using RA**

Characteristic	Value
Total Patients	112
Age (years)	68.4 ± 0.45 (range: 18-90)
Gender (Male)	75.8%
Diabetes Mellitus	35.7%
Acute Coronary Syndrome	>60%
LVEF (%)	54.0 ± 12.6
DAPT Prescribed	94.8%
Statins Prescribed	91.5%

**Table 2: Procedural Details and Outcomes**

Parameter	Value
Femoral Approach (%)	59.5%
Radial Approach (%)	40.5%
Stent Implantation (%)	95.0%
POBA (%)	2.0%
DEB (%)	2.8%
No Intervention (%)	1.5%
IVUS or OCT Utilized (%)	47.0%
Burr Size (most frequent: 1.5 mm)	54.8%
Technical Success Rate (%)	97.5%
Procedural Success Rate (%)	89.2%
Procedure Time (minutes)	64.5
Contrast Volume (ml)	220
Radiation Dose (mGy)	2695
MACCEs in-hospital (%)	13.3%
MI during Procedure (%)	4.46%
Death in-hospital (%)	9.8%
CVA in-hospital (%)	1.7%
Severe Coronary Dissection (%)	7.14%
Coronary Perforation (%)	3.5%
Interventions Requiring Cardiac Tamponade (%)	1.78%

[Citation: Aslam, K., Iqbal, E., Khan, F.R., Sajjad, W., Khan, M.S. (2023). Outcomes of rotational atherectomy in calcified proximal left anterior descending (LAD) lesions in the context of triple vessel disease. *Biol. Clin. Sci. Res. J.*, 2023: 603. doi: <https://doi.org/10.54112/bcsrj.v2023i1.603>]

## Discussion

Fundamental discoveries arising from our investigation can be summarized as follows: Firstly, the success rates in both the technical and procedural aspects of rotational atherectomy (RA) were satisfactory, particularly in the context of heavily calcified proximal left anterior descending (LAD) lesions. Secondly, the utilization of RA during percutaneous coronary intervention (PCI) emerged as a secure and effective approach for revascularization, demonstrating positive outcomes in terms of ‘in-hospital major adverse cerebral and cardiac events (MACCEs)’ and procedural complications. Additionally, various procedural metrics, including procedure timings, quantity of contrast, and radiation dosage, were within acceptable parameters. Thirdly, our registry analysis unveiled independent predictors of target vessel failure (TVF). Patients undergoing PCI predominantly received implantation of drug-eluting stents (DESs), with a notable preference for 2nd generation DES. However, an exception was observed in one patient who received a 1st generation DES. This trend may provide insights into the evolving clinical landscape of ‘RA’ in the ‘2<sup>nd</sup> generation DES era’. Notably, ‘dual antiplatelet therapy (DAPT)’ and ‘statin’ prescriptions surpassed 90% within the study population, aligning with contemporary guidelines (Grundy et al., 2019; Levine et al., 2016; Patti et al., 2019).

Every case examined exhibited calcification, and in 38% of instances, rotational atherectomy (RA) was initiated due to the inadequacy of dilatation using a 3.0 mm or enormous balloon. In the remaining cases, the decision to employ RA was made promptly at the discretion of the operator, guided by diverse factors such as angiographic observations, the calcifications evident in intra-vascular images, and the resistance encountered with smaller balloons or wires. Despite offering data showcasing acceptable efficacy outcomes in terms of success rates and procedural results, we consistently achieved a final Thrombolysis in Myocardial Infarction (TIMI) score of 3 in 96.4% of all cases, aligning with outcomes observed in prior investigations (Abdel-Wahab et al., 2013; Cortese et al., 2016; Kawamoto et al., 2016; Okai et al., 2018; Rathore et al., 2010). Notably, the procedure timings and contrast quantity values were comparatively smaller than those reported in a previous study (Kawamoto et al., 2016).

The cohort under study comprised individuals grappling with advanced coronary atherosclerosis and substantial comorbidities. Remarkably, diabetes afflicted over half of the participants, and the majority presented with triple vessel diseases. Per prevailing guidelines, coronary artery bypass grafting (CABG) is typically recommended for the revascularization of triple vessel disease accompanied by diabetes (Patel et al., 2017; Roffi et al., 2015). However, owing to the heightened risks associated with peri-operative mortality and morbidity, coupled with patient preferences, operators in this registry opted for percutaneous coronary intervention (PCI) with rotational atherectomy (RA) as an alternative to CABG. While in-hospital ‘major adverse cerebral and cardiac events (MACCEs)’ and procedural complications demonstrated viable and acceptable outcomes in comparison to prior studies (Abdel-Wahab et al., 2013; Cortese et al., 2016; Kawamoto et al., 2016; Okai et al., 2018; Rathore et al., 2010), the occurrence of in-hospital MACCEs was predominantly driven by MI during

the procedure, which manifested higher rates than in past research. Plausible explanations for this disparity include the inclusion of over 60% acute coronary syndrome (ACS) patients in our study and the recording of events based on a tenfold rise of cardiac enzymes (CK-MB) in healthcare records, potentially resulting in overestimations.

## Limitation

Our study possesses several inherent limitations. Firstly, it was a non-randomized observational study, and data was collected retrospectively, which inherently introduces potential biases. Moreover, a relatively confined number of participants, coupled with a limited duration of follow-ups, render the assessment of long-lasting outcomes challenging. Additionally, crucial parameters reflecting lesion complexity, such as the “SYNTAX score” or “quantitative coronary angiography,” were not incorporated into our analysis, limiting a comprehensive understanding of the intricacies of the lesions. Therefore, the generalizability and reliability of our findings necessitate further scrutiny, mainly through a reevaluation that encompasses these additional parameters.

## Conclusion

Our study has contributed to a substantial registry, offering insights into both healthcare and long-lasting rotational atherectomy (RA) results in calcified proximal left anterior descending (LAD) lesions within the context of triple vessel disease. The findings indicate acceptable success rates within the hospital and long-lasting clinical results, providing valuable information for understanding RA's efficacy in this specific patient population.

## Declarations

### Data Availability statement

All data generated or analyzed during the study are included in the manuscript.

### Ethics approval and consent to participate

Approved by the department Concerned.

### Consent for publication

Approved

### Funding

Not applicable

## Conflict of interest

The authors declared absence of conflict of interest.

## Author Contribution

### KAMRAN ASLAM (Trainee Medical Officer)

Coordination of collaborative efforts.

Study Design, Review of Literature.

Conception of Study, Development of Research Methodology Design, Study Design, Review of manuscript, final approval of manuscript.

### ERUM IQBAL (Trainee Medical Officer)

Conception of Study, Final approval of manuscript

Manuscript revisions, critical input.

FAHAD RAJA KHAN (FCPS Fellow Cardiology)

Coordination of collaborative efforts.

Data acquisition, analysis.

**WASIM SAJJAD (Fellow Interventional Cardiology)**

Manuscript drafting.

Data entry and Data analysis, drafting article.

**MUHAMMAD SHAHBAZ KHAN (Medical Officer)**

Data acquisition, analysis.

Coordination of collaborative efforts.

## References

- Abdel-Wahab, M., Baev, R., Dieker, P., Kassner, G., Khattab, A. A., Toelg, R., Sulimov, D., Geist, V., and Richardt, G. (2013). Long-term clinical outcome of rotational atherectomy followed by drug-eluting stent implantation in complex calcified coronary lesions. *Catheterization and Cardiovascular Interventions* **81**, 285-291.
- Ahn, S. S., Auth, D., Marcus, D. R., and Moore, W. S. (1988). Removal of focal atheromatous lesions by angioscopically guided high-speed rotary atherectomy: Preliminary experimental observations. *Journal of vascular surgery* **7**, 292-300.
- Barbato, E., Carrié, D., Dardas, P., Fajadet, J., Gaul, G., Haude, M., Khashaba, A., Koch, K., Meyer-Gessner, M., and Palazuelos, J. (2015). European expert consensus on rotational atherectomy. *EuroIntervention* **11**, 30-36.
- Benezet, J., de la Llera, L. S. D., María Cubero, J., Villa, M., Fernández-Quero, M., and Sánchez-González, Á. (2011). Drug-eluting stents following rotational atherectomy for heavily calcified coronary lesions: long-term clinical outcomes. *Journal of Invasive Cardiology* **23**, 28.
- Cortese, B., Aranzulla, T. C., Godino, C., Chizzola, G., Zavalloni, D., Tavasci, E., De Benedictis, M., Etori, F., Presbitero, P., and Colombo, A. (2016). Drug-eluting stent use after coronary atherectomy: results from a multicentre experience—The ROTALINK I study. *Journal of Cardiovascular Medicine* **17**, 665-672.
- De Maria, G. L., Scarsini, R., and Banning, A. P. (2019). Management of calcific coronary artery lesions: is it time to change our interventional therapeutic approach? *JACC: Cardiovascular Interventions* **12**, 1465-1478.
- Grundy, S. M., Stone, N. J., Bailey, A. L., Beam, C., Birtcher, K. K., Blumenthal, R. S., Braun, L. T., De Ferranti, S., Faiella-Tommasino, J., and Forman, D. E. (2019). 2018 AHA/ACC/AACVPR/AAPA/ABC/ACPM/ADA/AGS/APhA/ASPC/NLA/PCNA guideline on the management of blood cholesterol: a report of the American College of Cardiology/American Heart Association Task Force on Clinical Practice Guidelines. *Circulation* **139**, e1082-e1143.
- Hill, J. M., Kereiakes, D. J., Shlofmitz, R. A., Klein, A. J., Riley, R. F., Price, M. J., Herrmann, H. C., Bachinsky, W., Waksman, R., and Stone, G. W. (2020). Intravascular lithotripsy for treatment of severely calcified coronary artery disease. *Journal of the American College of Cardiology* **76**, 2635-2646.
- Jinnouchi, H., Kuramitsu, S., Shinozaki, T., Kobayashi, Y., Hiromasa, T., Morinaga, T., Mazaki, T., Sakakura, K., Soga, Y., and Hyodo, M. (2015). Two-year clinical outcomes of newer-generation drug-eluting stent implantation following rotational atherectomy for heavily calcified lesions. *Circulation Journal* **79**, 1938-1943.
- Kawamoto, H., Latib, A., Ruparelina, N., Ielasi, A., D'Ascenzo, F., Pennacchi, M., Sardella, G., Garbo, R., Meliga, E., and Moretti, C. (2016). In-hospital and midterm clinical outcomes of rotational atherectomy followed by stent implantation: the ROTATE multicentre registry. *EuroIntervention* **12**, 1448-1456.
- Lee, M. S., Gordin, J. S., Stone, G. W., Sharma, S. K., Saito, S., Mahmud, E., Chambers, J., Généreux, P., and Shlofmitz, R. (2018). Orbital and rotational atherectomy during percutaneous coronary intervention for coronary artery calcification. *Catheterization and Cardiovascular Interventions* **92**, 61-67.
- Levine, G. N., Bates, E. R., Bittl, J. A., Brindis, R. G., Fihn, S. D., Fleisher, L. A., Granger, C. B., Lange, R. A., Mack, M. J., and Mauri, L. (2016). 2016 ACC/AHA guideline focused update on duration of dual antiplatelet therapy in patients with coronary artery disease: a report of the American College of Cardiology/American Heart Association Task Force on Clinical Practice Guidelines: an update of the 2011 ACCF/AHA/SCAI guideline for percutaneous coronary intervention, 2011 ACCF/AHA guideline for coronary artery bypass graft surgery, 2012 ACC/AHA/ACP/AATS/PCNA/SCAI/STS guideline for the diagnosis and management of patients with stable ischemic heart disease, 2013 ACCF/AHA guideline for the management of ST-elevation myocardial infarction, 2014 AHA/ACC guideline for the management of patients with non-ST-elevation acute coronary syndromes, and 2014 ACC/AHA guideline on perioperative cardiovascular evaluation and management of patients undergoing noncardiac surgery. *Circulation* **134**, e123-e155.
- Mezilis, N., Dardas, P., Ninios, V., and Tsikaderis, D. (2010). Rotablation in the drug eluting era: Immediate and long-term results from a single center experience. *Journal of interventional cardiology* **23**, 249-253.
- Okai, I., Dohi, T., Okazaki, S., Jujo, K., Nakashima, M., Otsuki, H., Tanaka, K., Arashi, H., Okabe, R., and Nagura, F. (2018). Clinical Characteristics and Long-Term Outcomes of Rotational Atherectomy—J2T Multicenter Registry—. *Circulation Journal* **82**, 369-375.
- Patel, M. R., Calhoun, J. H., Dehmer, G. J., Grantham, J. A., Maddox, T. M., Maron, D. J., and Smith, P. K. (2017). ACC/AATS/AHA/ASE/ASNC/SCAI/SCCT/STS 2017 appropriate use criteria for coronary revascularization in patients with stable ischemic heart disease: a report of the American College of Cardiology appropriate use criteria task force, American Association for Thoracic Surgery, American Heart Association, American Society of Echocardiography, American Society of Nuclear Cardiology, Society for Cardiovascular Angiography and Interventions, Society of Cardiovascular Computed Tomography, and Society of Thoracic Surgeons. *Journal of the American College of Cardiology* **69**, 2212-2241.
- Patti, A. M., Giglio, R. V., Papanas, N., Rizzo, M., and Rizvi, A. A. (2019). Future perspectives of the pharmacological management of diabetic dyslipidemia. *Expert Review of Clinical Pharmacology* **12**, 129-143.
- Rathore, S., Matsuo, H., Terashima, M., Kinoshita, Y., Kimura, M., Tsuchikane, E., Nasu, K., Ehara, M., Asakura, Y., and Katoh, O. (2010). Rotational atherectomy for fibrocalcific coronary artery disease in drug eluting stent era: Procedural outcomes and angiographic follow-up results. *Catheterization and Cardiovascular Interventions* **75**, 919-927.
- Roffi, M., Patrono, C., Collet, J.-P., Mueller, C., Valgimigli, M., Andreotti, F., Bax, J. J., Borger, M. A., Brotons, C., and Chew, D. P. (2015). 2015 ESC Guidelines for the management of acute coronary syndromes in patients presenting without persistent ST-segment elevation. *Kardiologia Polska (Polish Heart Journal)* **73**, 1207-1294.
- Tamekiyo, H., Hayashi, Y., Toyofuku, M., Ueda, H., Sakuma, T., Okimoto, T., Otsuka, M., Imazu, M., and Kihara, Y. (2009). Clinical outcomes of sirolimus-eluting stenting after rotational atherectomy. *Circulation Journal* **73**, 2042-2049.

[Citation: Aslam, K., Iqbal, E., Khan, F.R., Sajjad, W., Khan, M.S. (2023). Outcomes of rotational atherectomy in calcified proximal left anterior descending (LAD) lesions in the context of triple vessel disease. *Biol. Clin. Sci. Res. J.*, 2023: 603. doi: <https://doi.org/10.54112/bcsrj.v2023i1.603>]

Tomey, M. I., Kini, A. S., and Sharma, S. K. (2014). Current status of rotational atherectomy. *JACC: Cardiovascular Interventions* 7, 345-353.



**Open Access** This article is licensed under a Creative Commons Attribution 4.0 International License, which permits use, sharing, adaptation, distribution and reproduction in any medium or format, as long as you give appropriate credit to the original author(s) and the source, provide a link to the Creative Commons licence, and indicate if changes were made. The images or other third party material in this article are included in the article's Creative Commons licence, unless indicated otherwise in a credit line to the material. If material is not included in the article's Creative Commons licence and your intended use is not permitted by statutory regulation or exceeds the permitted use, you will need to obtain permission directly from the copyright holder. To view a copy of this licence, visit <http://creativecommons.org/licenses/by/4.0/>. © The Author(s) 2023