

DIAGNOSTIC ACCURACY OF ULTRASONOGRAPHY IN DIFFERENTIATING BENIGN AND MALIGNANT THYROID NODULES

KHALIL SFK*, AWAN MW, KAMAL MM, AHMAD M, AMJAD M, HASEEB M

Department of Radiology, KRL Hospital, Islamabad, Pakistan

*Correspondence author email address: sanafarid1@hotmail.com

(Received, 05th August 2023, Revised 28th October 2023, Published 15th November 2023)

Abstract: *This study aimed to compare the effectiveness of ultrasonography and fine-needle aspiration cytology (FNAC) in distinguishing between benign and malignant thyroid nodules. To conduct this cross-sectional study, we obtained ethical approval from the institutional review board and collected data from KRL Hospital between December 1, 2021, and April 30, 2022. We included patients of either gender, aged 18 years or above, referred to the radiology department for diagnosis of benign or malignant thyroid nodules or FNAC of nodules, using non-probability consecutive sampling. After giving informed consent, all patients underwent high-resolution Gray ultrasonography performed by a consultant radiologist. The results showed that ultrasonography had a sensitivity of 90.62%, specificity of 88.37%, positive predictive value of 85.29%, negative predictive value of 92.68%, and an overall accuracy of 89.33% in detecting benign and malignant thyroid nodules, as compared to the gold standard, FNAC. Based on these findings, we conclude that ultrasonography is an excellent non-invasive diagnostic tool, with high accuracy and no invasiveness, making it the preferred method for identifying malignant thyroid nodules.*

Keywords: Thyroid Nodules, Diagnosis, Ultrasonography, Accuracy

Introduction

Thyroid nodules can be solid or cystic, but they are consistently abnormal. Thyroid nodules may be indicative of clinically severe thyroid carcinomas (Tareen et al., 2020). Thyroid nodules can be felt in 4–8% of people, 10–41% have nodules found by ultrasonography (intentionally or not), and 50% have nodules found by pathologic testing at the time of death (Avinash et al., 2016). Even though nodules are so widespread, thyroid cancer is rare; fortunately, results are improved by early detection and treatment (Andrioli et al., 2013). While most thyroid nodules are benign, 55% are cancerous, according to Ma JJ et al. (Ma et al., 2014). A thyroid nodule found during a regular physical examination may result in a referral to an endocrinologist or thyroidologist. The gold standard for determining whether a nodule is present and assessing the overall health of the gland is ultrasound (Kim et al., 2014). Measuring thyroid stimulating hormone and anti-thyroid antibodies can reveal the existence of a functional thyroid disease, such as Hashimoto's thyroiditis, which is known to generate a benign nodular goiter (Remonti et al., 2015). Testing for calcitonin is necessary to rule out thyroid cancer in the medullary gland. Lastly, to obtain a precise diagnosis before choosing a course of treatment, a fine needle aspiration cytology test is frequently performed and reported per the Bethesda protocol (Kim et al., 2015). For the diagnosis of non-toxic thyroid nodules, fine needle aspiration (FNA) has emerged as the gold standard for determining whether patients need surgery and whether they should have it. Ultrasonography is the most popular diagnostic technique for checking the thyroid (Kim et al., 2014). With this procedure, determining the number and size of nodules is simple and economical.

Nevertheless, using ultrasonography regarding thyroid nodule prioritization remains uncertain (Remonti et al.,

2015). The frequency of thyroid nodules identified by high-resolution ultrasonography has increased with the prevalence of asymptomatic thyroid malignancies, specifically papillary thyroid carcinoma and PTMCs (Kim et al., 2015). The use of ultrasonographic (US) features to differentiate between benign and malignant thyroid nodules has been the subject of a recent study (Maimaiti et al., 2016; Popli et al., 2012). In a study (Afifi et al., 2017), the overall results for the ultrasound diagnosis of benign and malignant thyroid nodules were 81.8% sensitivity, 87.2% specificity, 59.0% positive predictive value, and 95.5% negative predictive value. A different study discovered a 73% accuracy rate, 34% specificity, 85.4% PPV, 72.3% NPV, and 92% sensitivity (Zahir et al., 2016). According to the local inquiry, ultrasonography could differentiate between benign and malignant nodules with 93.2% specificity, 93.8% sensitivity, 98% positive predictive value, and 93.3% negative predictive value (Popli et al., 2012). This study aimed to evaluate the diagnostic performance of fine-needle aspiration cytology (FNAC) and ultrasonography in differentiating between benign and malignant thyroid nodules.

Methodology

After the ethical approval from the institutional review board, this cross-sectional study was conducted at KRL Hospital Islamabad from December 1, 2021, to April 30, 2022. Through non-probability consecutive sampling, patients referred to the radiology department for benign or malignant thyroid nodules diagnosis or FNAC of nodules above age 18 years of either gender were included in the study. Patients with already proven histopathology reports and previous thyroid surgery were excluded. A high-resolution Gray ultrasonography by a consultant radiologist

[Citation: Khalil, S.F.K., Awan, M.W., Kamal, M.M., Ahmad, M., Amjad, M., Haseeb, M. (2023). Diagnostic accuracy of ultrasonography in differentiating benign and malignant thyroid nodules. *Biol. Clin. Sci. Res. J.*, 2023: 545. doi: <https://doi.org/10.54112/bcsrj.v2023i1.545>]

was performed on all the patients after the informed consent. Ultrasound-guided FNAC was conducted by a radiologist in the affected ward, and a specimen was transferred to the institutional laboratory for histology, where the consultant histopathologist read the result. USG findings and the FNAC report were connected. Age, gender, the length of the nodule, its size, and whether it was benign or malignant were all noted on a particular proforma. The Medcalc online software was used to conduct the statistical analysis. To calculate the sensitivity and the positive and negative probability ratios, the results from the US were compared to those from the FNAC. The chi-square test was employed for categorical variables, while the t-test was utilized for continuous variables. P value ≤ 0.05 was considered significant.

Out of 150 patients, 90 (60%) were males and 50 (40%) were females, with an average of 45 ± 3.56 years. In the present study participants, the disease duration was 6.45 ± 2.4 months, and the mean nodule size observed was 3.8 ± 3.2 cm (Table 1). Of 150 participants, 58 were positive with nodules in both USG and FNAC, while 76 were negative in both the tests (P value < 0.0001 , Table 2)—diagnostic accuracy according to nodule size stratification represented in Tables 3 and 4. Figure 1-4 shows the ultrasonography results of nodules in the thyroid.

Table 1: Patient population distribution by nodule size

Nodule Size	N (%)
≤ 5 cm	87 (58%)
> 5 cm	63 (42%)

Results

Table 2: Evaluation of ultrasonography's ability to diagnose benign from malignant thyroid nodules, using fine-needle aspiration as the gold standard.

USG Result	FNAC Result		Total	P-Value
	Positive	Negative		
Positive	58 (True Positive)	10 (False Positive)	68	< 0.00001
Negative	6 (False Negative)	76 (True Negative)	82	
Total	64	86	150	
Sensitivity=90.62%	Specificity= 88.37%	PPV= 85.29%	NPV= 92.68%	Accuracy=89.33%

Table 3: Stratification of the size of nodule ≤ 5 cm

USG Result (N=87)	FNAC Result (N=87)		P-Value
	Positive	Negative	
Positive	38 (True Positive)	6 (False Positive)	< 0.00001
Negative	4 (False Negative)	39 (True Negative)	
Sensitivity= 90.48%	Specificity= 86.67%	PPV= 86.36%	NPV= 90.70%

Table 4: Stratification of the size of nodule > 5 cm

USG Result (N=63)	FNAC Result (N=63)		P-Value
	Positive	Negative	
Positive	30 (True Positive)	5 (False Positive)	< 0.00001
Negative	3 (False Negative)	25 (True Negative)	
Sensitivity= 90.91%	Specificity= 83.33%	PPV= 85.71%	NPV= 89.29%

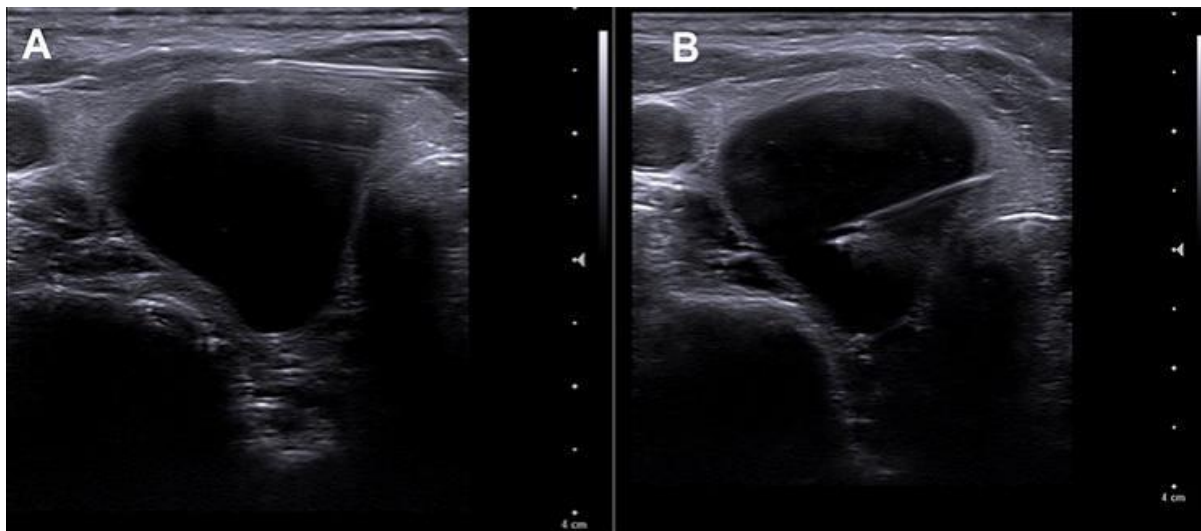


Figure 1: A- a cystic nodule was noted in the right lobe of the thyroid. B-FNAC needle seen in insitu of the cystic nodule

[Citation: Khalil, S.F.K., Awan, M.W., Kamal, M.M., Ahmad, M., Amjad, M., Haseeb, M. (2023). Diagnostic accuracy of ultrasonography in differentiating benign and malignant thyroid nodules. *Biol. Clin. Sci. Res. J.*, 2023: 545. doi: <https://doi.org/10.54112/bcsrj.v2023i1.545>]

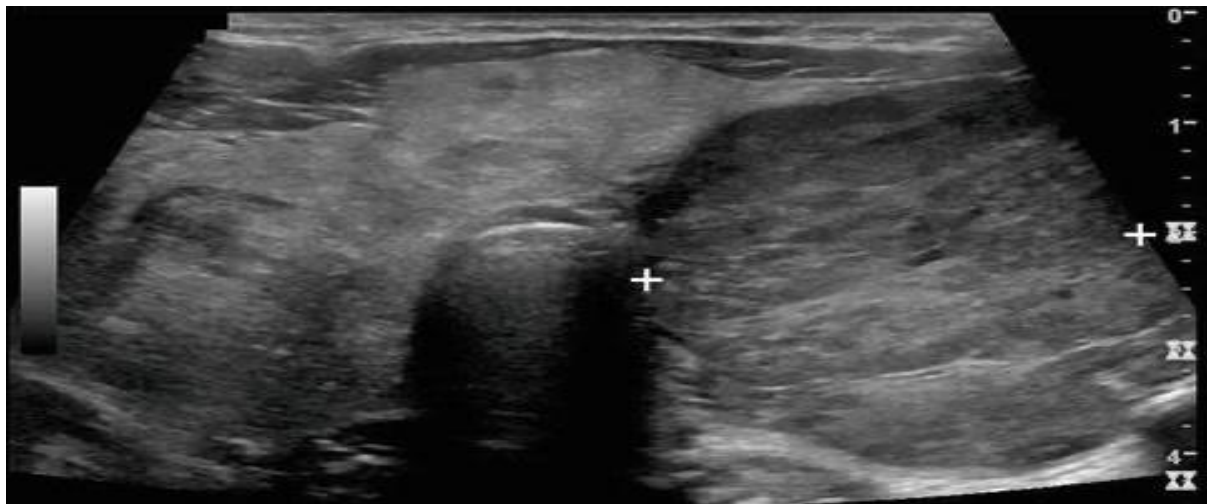

Figure 2: A large solid nodule in the left lobe of the thyroid.

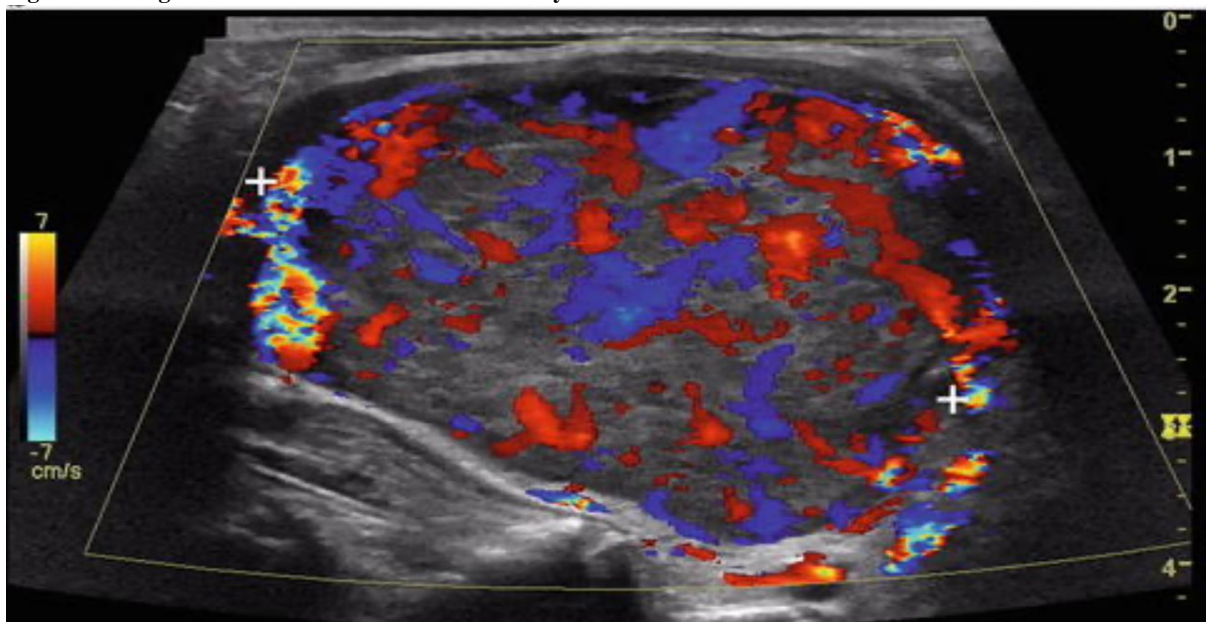


Figure 3: Solid nodule in the left lobe of the thyroid showing increased vascularity

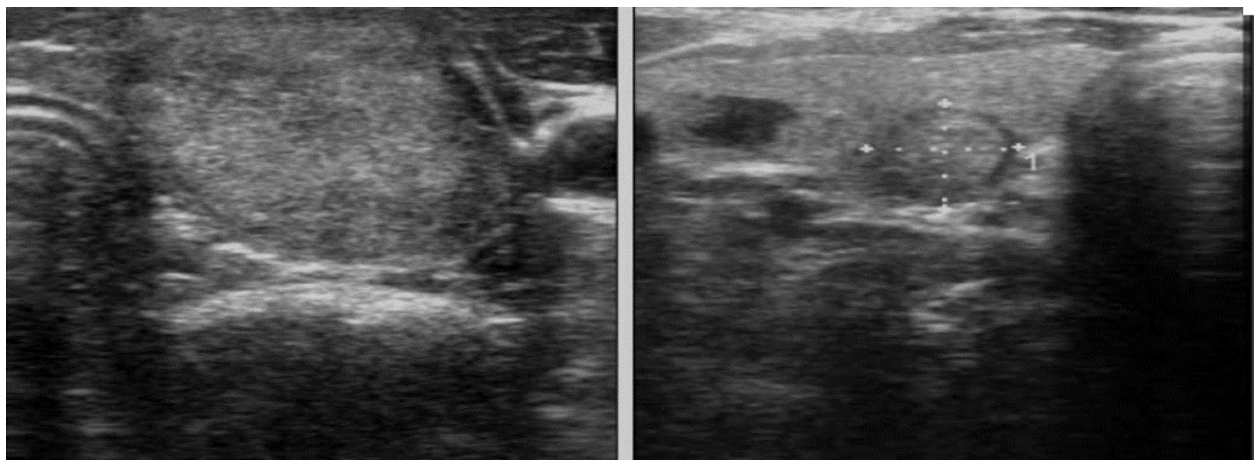


Figure 4: Benign wider than taller solid nodule with regular margins.

[Citation: Khalil, S.F.K., Awan, M.W., Kamal, M.M., Ahmad, M., Amjad, M., Haseeb, M. (2023). Diagnostic accuracy of ultrasonography in differentiating benign and malignant thyroid nodules. *Biol. Clin. Sci. Res. J.*, 2023: 545. doi: <https://doi.org/10.54112/bcsrj.v2023i1.545>]

Discussion

Thyroid illness without nodules affects three to seven percent of adults. High-resolution Ultrasonography (USG) can identify most of these cases even though they don't have any external symptoms (Avinash et al., 2016; Cooper et al., 2009; Moon et al., 2008; Mortensen et al., 1955). Thyroid carcinoma is sporadic, accounting for less than 1% of all cancer cases. Following surgical excision, the prognosis is outstanding. Given the prevalence of thyroid nodules, it's critical to establish a strategy for identifying individuals who require prompt surgery vs those who may be treated more conservatively (Mortensen et al., 1955). As per the American Thyroid Association's current care recommendations, all patients with thyroid nodules should undergo diagnostic USG, and in cases where the nodule seems to be malignant, FNAC should be performed (Moon et al., 2008). A number of characteristics of USGs, such as irregular edges, limited echogenicity, lack of surrounding halo, calcifications, and solid interior composition, have been investigated as potential markers of malignancy. This study examined the ability of ultrasonography to differentiate between benign and malignant thyroid nodules using the gold standard, fine-needle aspiration cytology. There were 150 patients in the current study; their average age was 453.56 years. Of these, 90 (60%) were men and 50 (40%) were women. The patients in this study had an average nodule size of 3.83.2 cm and an average disease duration of 6.452.4 months. Of 150 individuals, 58 had positive results for nodules on both the USG and FNAC, while 76 showed adverse effects (P 0.0001). When comparing ultrasonography to FNAC as the gold standard, the results show that it can accurately identify benign from malignant thyroid nodules with a sensitivity of 90.62%, specificity of 88.37, positive predictive value of 85.29%, negative predictive value of 92.68%, and accuracy of 89.33%. In a study (10), the overall results for the ultrasound diagnosis of benign and malignant thyroid nodules were 81.8% sensitivity, 87.2% specificity, 59.0% positive predictive value, and 95.5% negative predictive value. A different study (Zahir et al., 2016) found that the accuracy was 73%, the NPV was 72.3%, and the PPV was 85.4%. According to the local inquiry, ultrasonography could differentiate between benign and malignant nodules with 93.2% specificity, 93.8% sensitivity, 98% PPV, and 93.3% NPV (Popli et al., 2012). A total of 831 patients and 849 nodules (360 malignant and 489 benign) were included in a different study (17). The following were all statistically significant indicators of malignancy: diameter > height (sensitivity = 40.0%, specificity = 91.4%), spiculated margin (sensitivity = 48.3%, specificity = 98.1%), marked hypoechogenicity (sensitivity = 41.4%, specificity = 92.2%), microcalcification (sensitivity = 44.2%, specificity = 90.8%), and macro calcification (sensitivity = 9.7%, specificity = 96.1%). Cytopathology led Avinash B et al. (Avinash et al., 2016) to conclude that six were malignant. The presence of microcalcification (sensitivity 66.6% and specificity 98.4%); absence or thick incomplete halo (sensitivity 83.3% and specificity 82.8%); anteroposterior diameter more significant than the transverse diameter (sensitivity 50% and specificity 93.75%); irregular or poorly defined margins (sensitivity 83.3% and specificity 92.06%); and a markedly hypoechoic . Recent research by

Ghajarzadeh et al. established the diagnostic accuracy of US in identifying malignant thyroid nodules through a thorough review and meta-analysis of all available data. They claimed that the US is a reliable screening method that can detect and characterize thyroid nodules and can almost always rule out malignant illness. Yang et al. (Yang et al., 2013) assessed the usefulness of acoustic radiation force impulse (ARFI) imaging in differentiating between benign and malignant thyroid nodules in a research involving 182 patients who needed thyroid surgery. They discovered that ARFI imaging may help determine between benign and malignant thyroid nodules and has promising diagnostic usefulness in clinical applications. It is essential to consider the position of the measurements (Yang et al., 2013). Researchers Yang et al. discovered that US may be used to determine the thyroid nodule's risk of malignancy when attempting to differentiate between benign and malignant nodules (Ghajarzadeh et al., 2014). Zhuo et al. evaluated the diagnostic utility of conventional US in determining between malignancy and degenerating cystic thyroid nodules that mimic malignancy. The findings showed that the US improves the performance in the differential diagnosis of malignancy and thyroid nodule (Zhuo et al., 2014).

Conclusion

This research found that ultrasonography has significantly enhanced our capacity to diagnose malignant thyroid nodules and is the non-invasive modality of choice with excellent diagnostic accuracy. Preoperatively identifying cancerous thyroid nodules not only aids the surgeons in selecting the best options. Therefore, we advise regular ultrasound examination of all thyroid lesions to accurately identify any malignant thyroid nodules before surgery and choose the best surgical strategy.

Declarations

Data Availability statement

All data generated or analyzed during the study are included in the manuscript.

Ethics approval and consent to participate

Approved by the department Concerned.

Consent for publication

Approved

Funding

Not applicable

Conflict of interest

The authors declared absence of conflict of interest.

References

- Afifi, A. H., Alwafa, W. A. H. A., Aly, W. M., and Alhammadi, H. A. B. (2017). Diagnostic accuracy of the combined use of conventional sonography and sonoelastography in differentiating benign and malignant solitary thyroid nodules. *Alexandria Journal of Medicine* **53**, 21-30.
- Andrioli, M., Carzaniga, C., and Persani, L. (2013). Standardized ultrasound report for thyroid nodules: the

- endocrinologist's viewpoint. *European Thyroid Journal* **2**, 37-48.
- Avinash, B., Ahmed, N., Sreedevi, T., Swapna, C., Latha, R. M., and Babu, J. (2016). Role of ultrasonography to differentiate benign and malignant thyroid nodules in correlation with fine-needle aspiration cytology. *International journal of scientific study* **4**, 81-87.
- Cooper, D. S., Doherty, G. M., Haugen, B. R., Kloos, R. T., Lee, S. L., Mandel, S. J., Mazzaferri, E. L., McIver, B., Pacini, F., and Schlumberger, M. (2009). Revised American Thyroid Association management guidelines for patients with thyroid nodules and differentiated thyroid cancer: the American Thyroid Association (ATA) guidelines taskforce on thyroid nodules and differentiated thyroid cancer. *Thyroid* **19**, 1167-1214.
- Ghajarzadeh, M., Sodagari, F., and Shakiba, M. (2014). Diagnostic accuracy of sonoelastography in detecting malignant thyroid nodules: a systematic review and meta-analysis. *AJR Am J Roentgenol* **202**, W379-89.
- Kim, J. Y., Jung, S. L., Kim, M. K., Kim, T.-J., and Byun, J. Y. (2015). Differentiation of benign and malignant thyroid nodules based on the proportion of sponge-like areas on ultrasonography: imaging-pathologic correlation. *Ultrasonography* **34**, 304.
- Kim, S.-Y., Hwa Han, K., Jung Moon, H., Young Kwak, J., Youn Chung, W., and Kim, E.-K. (2014). Thyroid nodules with benign findings at cytologic examination: results of long-term follow-up with US. *Radiology* **271**, 272-281.
- Ma, J.-j., Ding, H., Xu, B.-h., Xu, C., Song, L.-j., Huang, B.-j., and Wang, W.-p. (2014). Diagnostic performances of various gray-scale, color Doppler, and contrast-enhanced ultrasonography findings in predicting malignant thyroid nodules. *Thyroid* **24**, 355-363.
- Maimaiti, Y., Sun, S., Liu, Z., Zeng, W., Liu, C., Wang, S., Xiong, Y., Guo, Y., Li, X., and Wang, Y. (2016). Diagnostic accuracy of ultrasonographic features for benign and malignant thyroid nodules smaller than 10 mm. *Int J Clin Exp Med* **9**, 6476-82.
- Moon, W.-J., Jung, S. L., Lee, J. H., Na, D. G., Baek, J.-H., Lee, Y. H., Kim, J., Kim, H. S., Byun, J. S., and Lee, D. H. (2008). Benign and malignant thyroid nodules: US differentiation—multicenter retrospective study. *Radiology* **247**, 762-770.
- Mortensen, J., Woolner, L. B., and Bennett, W. A. (1955). Gross and microscopic findings in clinically normal thyroid glands. *The Journal of Clinical Endocrinology & Metabolism* **15**, 1270-1280.
- Popli, M. B., Rastogi, A., Bhalla, P., and Solanki, Y. (2012). Utility of gray-scale ultrasound to differentiate benign from malignant thyroid nodules. *Indian Journal of Radiology and Imaging* **22**, 63-68.
- Remonti, L. R., Kramer, C. K., Leitao, C. B., Pinto, L. C. F., and Gross, J. L. (2015). Thyroid ultrasound features and risk of carcinoma: a systematic review and meta-analysis of observational studies. *Thyroid* **25**, 538-550.
- Tareen, A., Aamir, M. O., Ahmed, S. N., Anwar, J., Khan, S. U., Gul, P., shakeel Baber, K., and Khan, B. (2020). Diagnostic accuracy of ultrasonography in differentiating benign and malignant thyroid nodules, taking FNAC as gold standard. *PJR* **30**.
- Yang, C., Han, C., Wang, L., Feng, N., Wang, Y., and You, X. (2013). Exploration on an ultrasonographic imaging reporting and data system in malignancy grading of thyroid nodules. *Zhonghua Zhong liu za zhi [Chinese Journal of Oncology]* **35**, 758-763.
- Zahir, S. T., Vakili, M., Ghaneei, A., and Heidari, F. (2016). Ultrasound assistance in differentiating malignant thyroid nodules from benign ones. *Journal of Ayub Medical College Abbottabad* **28**, 644-649.
- Zhuo, J., Ma, Z., Fu, W., and Liu, S. (2014). Differentiation of benign from malignant thyroid nodules with acoustic

radiation force impulse technique. *The British journal of radiology* **87**, 20130263.



Open Access This article is licensed under a Creative Commons Attribution 4.0 International License, which permits use, sharing, adaptation, distribution and reproduction in any medium or format, as long as you give appropriate credit to the original author(s) and the source, provide a link to the Creative Commons licence, and indicate if changes were made. The images or other third party material in this article are included in the article's Creative Commons licence, unless indicated otherwise in a credit line to the material. If material is not included in the article's Creative Commons licence and your intended use is not permitted by statutory regulation or exceeds the permitted use, you will need to obtain permission directly from the copyright holder. To view a copy of this licence, visit <http://creativecommons.org/licenses/by/4.0/>. © The Author(s) 2023