

## FUNCTIONAL OUTCOME OF ARTHROSCOPIC ANTERIOR CRUCIATE LIGAMENT RECONSTRUCTION AUGMENTED WITH NATIVE ANTERIOR CRUCIATE LIGAMENT AS BIOLOGIC AUGMENTATION

ANWER MW, KHATTAK WA

*Orthopaedic B Department Hayatabad Medical Complex Peshawar, Pakistan*

\*Corresponding author's email address: [wasimanwar77wa@gmail.com](mailto:wasimanwar77wa@gmail.com)

(Received, 28<sup>th</sup> June 2023, Revised 16<sup>th</sup> October 2023, Published 24<sup>th</sup> October 2023)

**Abstract** Anterior Cruciate Ligament (ACL) injuries represent a significant challenge in orthopedic surgery and sports medicine. These injuries, often incurred during athletic activities, accidents, or even everyday movements, can lead to severe pain, instability, and a substantial reduction in an individual's quality of life. The current study was carried out to determine the functional outcome of arthroscopic ACL reconstruction augmented with native ACL fibers as biologic augmentation. This descriptive case series was conducted on 85 patients diagnosed with ACL injury. Outcome of arthroscopic ACL reconstruction augmented with native ACL fibers as biologic augmentation was determined using Lysholm score. Comparison of pre and postoperative Lysholm scores was assessed using Paired Samples T Test. The mean age of the patients was  $35.94 \pm 12.78$  years. The mean preoperative Lysholm score was  $44.05 \pm 4.54$ . The mean postoperative Lysholm score was  $88.19 \pm 4.80$ ; the difference was statistically significant ( $P = 0.0001$ ). We conclude that arthroscopic ACL reconstruction augmented with native ACL fibers achieved a satisfactory outcome with a statistically significant difference between preoperative and postoperative Lysholm score.

**Keywords:** Anterior cruciate ligament; Arthroscopy; Femoral tunnel; Knee

### Introduction

Anterior Cruciate Ligament (ACL) injuries represent a significant challenge in orthopedic surgery and sports medicine. These injuries, often incurred during athletic activities, accidents, or even everyday movements, can lead to severe pain, instability, and a substantial reduction in an individual's quality of life (Elkin et al., 2019; Hassan et al., 2023). To address these issues, ACL reconstruction has become the cornerstone of treatment, aiming to restore knee joint stability and function. While this surgical procedure has evolved considerably over the years, researchers and clinicians continuously seek ways to optimize further postoperative outcomes (Filbay and Grindem, 2019; Renz et al., 2023).

This innovative technique involves preserving and incorporating segments of the patient's torn ACL into the graft during the reconstruction procedure (Lima et al., 2018). By harnessing the intrinsic regenerative potential of these native fibers, this approach aims to enhance the healing process and improve the overall functionality of the reconstructed ligament (Dallo et al., 2017). The concept of biologic augmentation in ACL reconstruction stems from a profound understanding of the unique biological and biomechanical properties of the native ACL (Uchida et al., 2020). The ACL is a critical structure within

the knee joint, maintaining stability and facilitating normal movement. When it sustains an injury, the body's natural healing mechanisms are often insufficient to restore it to its original strength and function (Fleming et al., 2022). Traditional ACL reconstruction methods have relied on synthetic grafts or allografts, which, while effective to some extent, may not fully replicate the intricate biology of the native ligament (Baawa-Ameyaw et al., 2021). Using native ACL fibers as biological augmentation represents a paradigm shift in approaching ACL reconstruction. By preserving and integrating a patient's tissue, this technique seeks to mimic the natural ligament's composition, structure, and functionality (Vermeijden et al., 2020). The premise is that by doing so, we may promote a more physiological healing response, encourage tissue integration, and ultimately achieve better long-term outcomes for patients undergoing ACL reconstruction (Olmos et al., 2019; Rodriguez et al., 2019).

The outcomes of experimenting with various biologics at the tendon-bone junction, both in vitro and in vivo are mixed. Bioaugmentation promotes speedy recovery and healing (Harvey et al., 2005).

After augmenting the ACL, outcomes have improved. The way biology works and graft healing was shown to improve. Targeted bioaugmentation applications produce the best effects (Looney et al., 2020; Rodríguez-Merchán, 2021).

In this study, we will delve into the emerging field of arthroscopic ACL reconstruction augmented with native ACL fibers, shedding light on the underlying principles, surgical techniques, and the burgeoning body of evidence supporting its effectiveness. We explored this approach's potential benefits and drawbacks and its implications for active individuals, and patients seeking a return to their pre-injury lifestyle. Additionally, we will examine the current state of research and clinical outcomes associated with this innovative technique, aiming to provide clinicians, researchers, and patients with valuable insights into the promising future of biologic augmentation in ACL reconstruction.

#### Material and methods

This study presents a descriptive case series of 85 patients who sought medical care at the Orthopedics outpatient department of Hayatabad Medical Complex, Peshawar, from June 2022 to June 2023. The individuals in question were identified with Anterior Cruciate Ligament (ACL) injuries through clinical assessments and radiographic exams. The study encompassed a sample population of persons aged 18 to 55, irrespective of gender. The study excluded individuals with concomitant knee ligament injuries, including those requiring surgical reconstruction of the posterior Cruciate ligament, and persons who had previously undergone ACL reconstruction surgery. Patients with acute knee injuries on the opposite leg were omitted from the study. The sample size was determined using the openepi software, to achieve a 95% confidence interval and a 2% absolute precision. This determination considered the Lysholm score, estimated to be  $89.6 \pm 9.4$  (Su et al., 2020).

Consecutively eligible patients were enlisted in the study utilizing a non-probability sampling technique, and they were supplied with a comprehensive explanation regarding the purpose of the research. Following that, written informed consent was acquired from all patients chosen for the study. Upon admission, a complete patient history was obtained to get insight into the mechanism and severity of the injury. The participants in the study had comprehensive assessments encompassing physical examinations, clinical evaluations, and radiographic analyses. These evaluations included the acquisition of preoperative magnetic resonance imaging (MRI) scans.

The surgical procedures were conducted exclusively by a solitary surgeon, with patients being administered spinal anaesthetic. The knee joint underwent cleaning and draping, followed by the

inflation of a tourniquet around the thigh. The presence of the ACL remnant was detected using a 2-portal approach, encompassing the implementation of both typical central medial and anterolateral portals. The anterolateral portal was utilized as an observational portal throughout the drilling of the tibial insertion and acted as a functional portal throughout the surgical procedure. The central medial portal was positioned superior to the joint line and served as a means for observation or manipulation. Upon establishing both portals, the pattern of ACL rupture and the bone markers associated with the insertion of the ACL were recognized. A little surgical cut measuring approximately 2 cm was performed above the lateral malleolus to extract the peroneus longus tendon. The tendon was then followed to its point of attachment and released to achieve optimal length. The tendon was transformed into a quadrupled graft, measuring approximately 6.5 cm in length, using a graft preparation station manufactured by Arthrex. The tunnel's dimensions were determined based on the graft's dimensions and supplemented with the presence of native anterior cruciate ligament remains at the site of the tunnel.

After the completion of the surgical interventions, patients were subjected to periodic monitoring, which occurred at specific time intervals, namely 6 weeks, 3 months, and 6 months following the operation. Patient outcomes were assessed using the Lysholm score, a comprehensive tool comprising eight distinct items; each awarded a score on a progressive scale. The overall score spans from 0 to 100, with higher scores denoting superior results and reduced symptoms or handicap. The data about patient age, length from accident to surgery, injury mode, injured side, and functional outcomes were collected utilizing a pre-established Performa attached to this synopsis.

The data analysis was performed using SPSS Version 23.0. The mean and standard deviation were computed for the quantitative variables. The preoperative and postoperative Lysholm scores were subjected to statistical analysis using paired sample t-tests. The obtained data were then visually represented using tables and graphs.

#### Results

This study was conducted on 85 patients diagnosed with ACL injury. The mean age of the patients was  $35.94 \pm 12.78$  years. The statistics related to baseline characteristics are mentioned in table 1. Majority of the patients presented were in the age group of 15 to 40 years 51 (60%), while there were 43 (40%) patients in the age group of 41 to 55 years. Gender-wise, there were 52 (61.2%) male patients while 33 (38.8%) female patients. Fall turned out to be the leading cause of injuries, 40 (47.4%), while road traffic accidents were the second leading cause 27

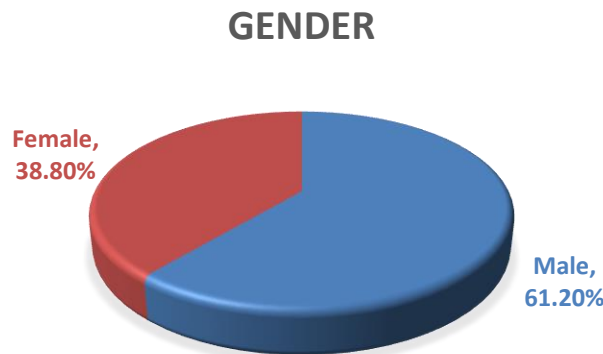
(31.8%), and sports accounted for 18 (21.2%) of the injuries. According to the comparison of preoperative and postoperative Lysholm score, the mean preoperative Lysholm score was 44.05±4.54

while the mean postoperative Lysholm score was 88.19±4.80; the difference was statistically significant (P = 0.0001).

**Table 1 Baseline characteristics**

Demographics		Statistics
Age (Years)		35.94±12.78
Duration of injury to surgery (Weeks)		12.82±6.24
BMI		26.62±2.26
Hypertension		15.3%
Diabetes		16.5%
Cardiovascular disease		10.6%
Side of injury	Left	57.6%
	Right	42.4%

**Figure 1 Gender distribution**



**Table 2: Comparison of preoperative and postoperative Lysholm score**

Variables	Mean	Std. Deviation	P value
Preoperative Lysholm score	44.05	4.543	0.0001
Postoperative Lysholm score	88.19	4.802	

**Discussion**

The native anterior cruciate ligament (ACL) exhibits a close and complicated association with the bone, establishing direct and indirect connections (Hexter et al., 2018). This results in the formation of a sophisticated and intricate framework that effectively transfers mechanical loads from soft tissue to the bone. The direct insertion of the anterior cruciate ligament (ACL) can be categorized into four morphological zones, each of which enables a progressive transition of the ligament into both cartilage and bone. The complicated relationship between the mechanical strains experienced at the ligament-bone contact and the nature of the extracellular matrix (ECM) in direct ligament insertion is evident. The creation of different molecules that contribute to cartilage formation is induced by the considerable compression stresses experienced at the insertion sites of ligaments (Milz

et al., 2005). The entheses contain several extracellular matrix (ECM) molecules, such as proteoglycans, glycosaminoglycans (GAGs), aggrecans, and binding proteins. These ECM molecules exhibit an increased abundance under compression. Furthermore, it has been shown that there is an elevation in the levels of chondroitin 6 sulfate, as opposed to chondroitin 4 sulfate, in fibrocartilage during periods of increased compression. Additional essential elements of the direct anterior cruciate ligament (ACL) insertion include certain collagens specific to cartilage, including kinds II, IX, X, and XI. Among these, collagen X is critical in preserving the interface between the non-mineralized and mineralized portions of the fibrocartilage (Takayama and Kuroda, 2017).

On the other hand, the indirect insertion of the anterior cruciate ligament (ACL) is facilitated by the presence of Sharpey fibers, which effectively fasten

[Citation Anwer, M.W., Khattak, W.A. (2023). Functional outcome of arthroscopic anterior cruciate ligament reconstruction augmented with native anterior cruciate ligament as biologic augmentation. *Biol. Clin. Sci. Res. J.*, 2023: 496. doi: <https://doi.org/10.54112/bcsrj.v2023i1.496>]

the ligament to the adjacent bone, thereby offering supplementary mechanical strength (Scheffler et al., 2008). After undergoing ACL repair, the complete restoration of the original ligament structure becomes unattainable due to the lack of fibrocartilage remodeling at the interface between the graft and the bone. In these particular cases, rather than the conventional establishment of the four progressive zones, tissue integration occurs via the production of a layer of fibrovascular scar tissue. This triggers the osteointegration process of the transplant. Over time, the interface experiences a gradual mineralization process, facilitating bone formation and the integration of graft material. In conclusion, restoring collagen fibers ultimately leads to reconstitution of the ligament-bone interface (Leite and Demange, 2019).

The mean age of our patients was  $35.94 \pm 12.78$  years; most were under 40, and the majority were male. We observed that fall was the leading cause of the ACL injuries presented. The mean postoperative Lysholm score was  $88.19 \pm 4.802$ , and the mean preoperative Lysholm score was  $44.05 \pm 4.543$  in our study; the difference was statistically significant. Our results agree with a study (Su et al., 2020) which reported that the mean postoperative Lysholm score was  $89.6 \pm 9.4$  and the mean preoperative Lysholm score was  $47.3 \pm 12.8$  with a statistically significant difference. Another study on patients under 21 years presenting with ACL reported significant improvement in Lysholm score postoperatively compared to the preoperative Lysholm score (Berdis et al., 2019).

To enhance the outcomes of ACL reconstruction, an increasing body of evidence indicates that augmenting biological processes can be beneficial for graft healing. The ACL's diverse histological origins make graft incorporation into the bone a multifaceted and gradual healing process, comprising osteointegration and intra-articular ligamentization phases. Various strategies aimed at improving ACL healing have been explored in orthopedic science. These approaches include using mesenchymal cells, platelet-rich plasma (PRP), gene therapies, and biophysical and pharmacological interventions (Leite and Demange, 2019).

### Conclusion

In conclusion, our study found that arthroscopic ACL reconstruction, augmented with native ACL fibers, resulted in a satisfactory outcome. A statistically significant difference between the preoperative and postoperative Lysholm scores indicated improved patient outcomes following the procedure.

### References

Baawa-Ameyaw, J., Plastow, R., Begum, F. A., Kayani, B., Jedy, H., and Haddad, F. (2021). Current concepts in graft selection for anterior

cruciate ligament reconstruction. *EFORT Open Reviews* **6**, 808-815.

- Berdis, A. S., Veale, K., and Fleissner Jr, P. R. (2019). Outcomes of anterior cruciate ligament reconstruction using biologic augmentation in patients 21 years of age and younger. *Arthroscopy: The Journal of Arthroscopic & Related Surgery* **35**, 3107-3113.
- Dallo, I., Chahla, J., Mitchell, J. J., Pascual-Garrido, C., Feagin, J. A., and LaPrade, R. F. (2017). Biologic approaches for the treatment of partial tears of the anterior cruciate ligament: a current concepts review. *Orthopaedic journal of sports medicine* **5**, 2325967116681724.
- Elkin, J. L., Zamora, E., and Gallo, R. A. (2019). Combined anterior cruciate ligament and medial collateral ligament knee injuries: anatomy, diagnosis, management recommendations, and return to sport. *Current Reviews in Musculoskeletal Medicine* **12**, 239-244.
- Filbay, S. R., and Grindem, H. (2019). Evidence-based recommendations for the management of anterior cruciate ligament (ACL) rupture. *Best Practice & Research Clinical Rheumatology* **33**, 33-47.
- Fleming, J. D., Ritzmann, R., and Centner, C. (2022). Effect of an anterior cruciate ligament rupture on knee proprioception within 2 Years after conservative and operative treatment: A systematic review with meta-analysis. *Sports Medicine*, 1-12.
- Harvey, A., Thomas, N., and Amis, A. (2005). Fixation of the graft in reconstruction of the anterior cruciate ligament. *The Journal of Bone & Joint Surgery British Volume* **87**, 593-603.
- Hassan, N., Amin, F., Bashir, K., Irshad, M., Jamil, S., Munawar, N., Haqqani, H., Shabir, H., & Khan, M. (2023). Antiviral response of drugs used against HBV patients of Khyber Pakhtunkhwa, Pakistan. *Bulletin of Biological and Allied Sciences Research*, **2023**(1), 49. <https://doi.org/10.54112/bbasr.v2023i1.49>
- Hexter, A., Thangarajah, T., Blunn, G., and Haddad, F. (2018). Biological augmentation of graft healing in anterior cruciate ligament reconstruction: a systematic review. *The Bone & Joint Journal* **100**, 271-284.
- Leite, C. B. G., and Demange, M. K. (2019). Biological enhancements for anterior cruciate ligament reconstruction. *Acta ortopedica brasileira* **27**, 325-330.
- Lima, D. A. d., Helito, C. P., Lima, F. R. A. d., and Leite, J. A. D. (2018). Surgical indications for anterior cruciate ligament reconstruction combined with extra-articular lateral tenodesis or anterolateral ligament reconstruction. *Revista brasileira de ortopedia* **53**, 661-667.

- Looney, A. M., Leider, J. D., Horn, A. R., and Bodendorfer, B. M. (2020). Bioaugmentation in the surgical treatment of anterior cruciate ligament injuries: A review of current concepts and emerging techniques. *SAGE Open Medicine* **8**, 2050312120921057.
- Milz, S., Benjamin, M., and Putz, R. (2005). Molecular parameters indicating adaptation to mechanical stress in fibrous connective tissue.
- Olmos, M. I., Sonnery-Cottet, B., and Barth, J. (2019). How to succeed in arthroscopic anterior cruciate ligament primary repair? Step-by-step technique. *Arthroscopy Techniques* **8**, e37-e46.
- Renz, N., Madjarevic, T., Ferrari, M., Becker, R., Ravn, C., Vogely, C., and Pérez-Prieto, D. (2023). Recommendations on diagnosis and antimicrobial treatment of infections after anterior cruciate ligament reconstruction (ACL-R) endorsed by ESSKA and EBJIS. *Journal of Infection* **86**, 543-551.
- Rodríguez-Merchán, E. C. (2021). Anterior cruciate ligament reconstruction: Is biological augmentation beneficial? *International Journal of Molecular Sciences* **22**, 12566.
- Rodriguez, R. M., Marroquin, A., and Cosby, N. (2019). Reducing fear of reinjury and pain perception in athletes with first-time anterior cruciate ligament reconstructions by implementing imagery training. *Journal of sport rehabilitation* **28**, 385-389.
- Scheffler, S. U., Unterhauser, F. N., and Weiler, A. (2008). Graft remodeling and ligamentization after cruciate ligament reconstruction. *Knee Surgery, Sports Traumatology, Arthroscopy* **16**, 834-842.
- Su, C., Kuang, S. d., Liu, W. j., Li, Y. s., Xiong, Y. l., Zhao, X., and Gao, S. g. (2020). Clinical Outcome of Remnant-Preserving and IDEAL Femoral Tunnel Technique for Anterior Cruciate Ligament Reconstruction. *Orthopaedic Surgery* **12**, 1693-1702.
- Takayama, K., and Kuroda, R. (2017). Biological augmentation of anterior cruciate ligament grafts. *Operative Techniques in Orthopaedics* **27**, 33-37.
- Uchida, R., Jacob, G., Shimomura, K., Horibe, S., and Nakamura, N. (2020). Biological augmentation of ACL repair and reconstruction: Current status and future perspective. *Sports Medicine and Arthroscopy Review* **28**, 49-55.
- Vermeijden, H. D., van der List, J. P., and DiFelice, G. S. (2020). Arthroscopic primary repair of the anterior cruciate ligament with single-bundle graft augmentation. *Arthroscopy Techniques* **9**, e367-e373.

## Declarations

### Data Availability statement

All data generated or analyzed during the study are included in the manuscript.

### Ethics approval and consent to participate

Not applicable

### Consent for publication

Not applicable

### Funding

Not applicable

### Conflict of Interest

Regarding conflicts of interest, the authors state that their research was carried out independently without any affiliations or financial ties that could raise concerns about biases.



**Open Access** This article is licensed under a Creative Commons Attribution 4.0 International License, which permits use, sharing, adaptation, distribution and reproduction in any medium or format, as long as you give appropriate credit to the original author(s) and the source, provide a link to the Creative Commons licence, and indicate if changes were made. The images or other third party material in this article are included in the article's Creative Commons licence, unless indicated otherwise in a credit line to the material. If material is not included in the article's Creative Commons licence and your intended use is not permitted by statutory regulation or exceeds the permitted use, you will need to obtain permission directly from the copyright holder. To view a copy of this licence, visit <http://creativecommons.org/licenses/by/4.0/>. © The Author(s) 2023