

INCIDENCE OF SHOULDER-TIP PAIN IN LAP. CHOLECYSTECTOMY NORMAL VERSUS LOW-PRESSURE PNEUMOPERITONEUM

NAEEMI MF

Department of Surgery, Surgical Unit-3 Allied Hospital, Faisalabad, Pakistan

*Correspondence author email address: faisalnaeemi499@gmail.com

(Received, 27th June 2023, Revised 20th September 2023, Published 28th October 2023)

Abstract: *Open cholecystectomy can lead to several post-operative complications. However, with the advent of minimal access surgery, these complications have decreased to a large extent. Nowadays, laparoscopic cholecystectomy is considered the gold standard for cholelithiasis. Similar to other surgeries, some post-operative complications are linked to laparoscopic surgery. One such complication is shoulder-tip pain. This study aimed to compare the intensity of post-op shoulder-tip pain after laparoscopic cholecystectomy at low pressure (10mmHg or less than 10mmHg) and standard pressure (12-14mmHg). Two groups of 30 patients each were made in this prospective randomized study. Group A patients underwent low-pressure pneumoperitoneum cholecystectomy (10mmHg or less than 10mmHg), while group B underwent standard-pressure pneumoperitoneum cholecystectomy (12-15mmHg). According to the verbal pain intensity score, post-op shoulder-tip pain was reduced in Group A compared to Group B at 6, 12, and 24 postoperative hours. This study showed that using low-pressure pneumoperitoneum in laparoscopic cholecystectomy reduces the intensity of post-operative shoulder pain and the need for analgesia.*

Keywords: Post-op shoulder-tip pain. Low-pressure pneumoperitoneum vs standard pressure peritoneum. Post-op analgesia demand.

Introduction

Minimal access surgery reduces wound access trauma, decreasing disfiguring than conventional techniques. One of them is laparoscopic cholecystectomy. Due to its minor incision compared to the open technique, it has become a gold standard treatment for gallstone disease (McSherry, 1989). Surgeons use available techniques and the latest apparatus to the best of their knowledge and skills, intending to promote the safest and most rapid return of the patient to a normal, healthy lifestyle while reducing mortality, morbidity, dysfunction, and pain. Despite their utmost effort, post-operative shoulder tip pain is complained about by many patients. Comprehensive analysis of complicated etiological causes is difficult. Pneumoperitoneum for the lap. Cholecystectomy is created by the insufflation of carbon dioxide intraperitoneally and maintaining its pressure until the end of surgery (Chok et al., 2006). One of the leading causes of shoulder tip pain is diaphragmatic irritation due to its stretching caused by pneumoperitoneum or carbon dioxide absorption from the peritoneal lining (Wallace et al., 1997). Shoulder tip pain is so strong that it requires analgesia frequently. Recorded figures for shoulder-tip pain range from 30 to 50% after laparoscopic cholecystectomy (Semm and Riedel, 1980). Some surgeons use standard 14-15 mmHg for CO₂ insufflation, but some authors decided that low-pressure pneumoperitoneum 10mmHg or less results in decreased post-op shoulder tip pain (Barczyński and Herman, 2004; Dexter et al., 1995; Perrakis et al., 2003; Sarli et al., 2000). However, while operating on low pressure, a few surgeons face difficulties regarding less working space, longer per-operative time, and a higher rate of per-operative complications leading to conversion to standard pressure pneumoperitoneum. There is a different opinion of surgeons about ideal pressure for

the lap. Cholecystectomy depending upon their experience and surgical skills. Our study aims to choose ideal pneumoperitoneal pressure that allows sufficient working space with lesser side effects especially that reduces post-operative shoulder tip pain. This prospective randomized study compares low-pressure pneumoperitoneum (LPP as <10mmHg) to standard high-pressure pneumoperitoneum (HPP>14mmHg). The main area of interest was post-operative shoulder tip pain.

Methodology

The study was conducted in Surgical Unit 3 of the Allied Hospital, affiliated with Faisalabad Medical University in Faisalabad, Punjab, Pakistan, for seven months. The participants considered for inclusion were aged between 12 and 65 years, with symptomatic cholelithiasis and without complications of gallstones. Inclusion criteria involved patients classified as ASA-1 to ASA-3. Exclusion criteria comprised individuals with a history of ERCP and stents in situ, known shoulder disease, empyema of the gallbladder, cholangitis, a history of multiple abdominal surgeries, coagulopathy, previous malignancy, ongoing pregnancy, patients undergoing laparoscopic cholecystectomy converted to open cholecystectomy, and those on chronic analgesic use due to arthritis or other ailments. Sixty eligible patients who met the inclusion criteria were randomized into two groups.

All patients underwent preoperative preparations, including overnight fasting and premedication with a 0.5mg oral tablet of Alprazolam on the night before surgery. In the operating theater, monitors were attached to measure blood pressure, continuous pulse rate, oxygen saturation, and continuous ECG monitoring. Preoperative intravenous Ceftriaxone was

administered to all patients at the operation table during the induction of anesthesia. The general anesthesia protocol was standardized for all patients. A standard laparoscopic cholecystectomy was performed, utilizing four standard ports for the laparoscopic camera (10 mm, umbilical port), right-hand working instrument (10 mm, epigastric port), left-hand working instrument (5 mm, right hypochondrium port), and gall bladder retraction (5 mm, right lumbar port) (Haribhakti and Mistry, 2015). All patients received intramuscular Ketorolac 30mg post-operatively every 8 hours for pain management.

Postoperative pain was assessed using a verbal pain intensity scale, which included categories of "no pain," "mild," "discomforting," "distressing," "horrible," and "excruciating." Patients reporting pain despite regular 8-hourly analgesia were administered an additional dose of intravenous Ketorolac on-demand. An on-duty staff nurse documented the dose and timing of these injections an on-duty staff nurse documented timing of these injections.

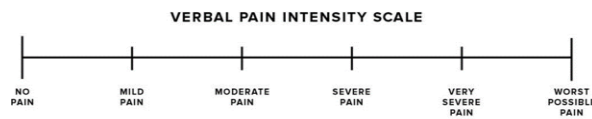


Figure 1: grades of the verbal pain intensity scale.

Results

patients were analyzed with a mean age of 42.2 with a male-to-female ratio of 12%:88%. Pneumoperitoneal pressure of 10mmHg or less was taken as low-pressure pneumoperitoneum (LPP) designated as Group A, pressure

of more than 10mmHg to standard pressure of 14- 15mmHg was taken as high-pressure pneumoperitoneum (HPP) designated as Group B. Ratio of HPP to LPP be: 50%:50. Both groups were compared on the bases of age, male, female ratio.

Female preponderance was found for cholelithiasis. The pain was assessed at 6, 12, and 24 hours post-operatively, using a verbal pain intensity scale. All patients from group B showed pain after 6 hours post-op, while 23% of patients from group A experienced no pain. After 6 hours post-operatively. 20% of group B showed mild pain, 80% experienced moderate pain, while 77% of patients from group A experienced moderate pain at 6 hours post-operatively. 13% showed no pain.

At postoperative 12 hours, Group B showed a mixed pattern of mild and moderate pain; 73% showed moderate pain, and 27 % showed mild shoulder tip pain, while a significant difference was observed in pain pattern at 12 hours in group A, 60% patients got no pain at all, 13% showed moderate pain and 7% experienced mild shoulder-tip pain only. Similarly, marked differences were observed if we compared pain statistics 24 hours post-operatively.50% of patients in Group B experienced moderate pain, 23% got mild pain, and 27% got their pain resolved. 80% of patients from group A got rid of their shoulder pain, and 13% showed mild pain. In contrast, only 7% experienced moderate pain intensity according to the verbal pain intensity scale, as shown in Figure 2. In HPP group B, 50% of patients required additional analgesia within the first 24 hours, while in LPP Group A, only 17% of patients required analgesia in addition to a regular 8-hour analgesic dose, as shown in Figure 3

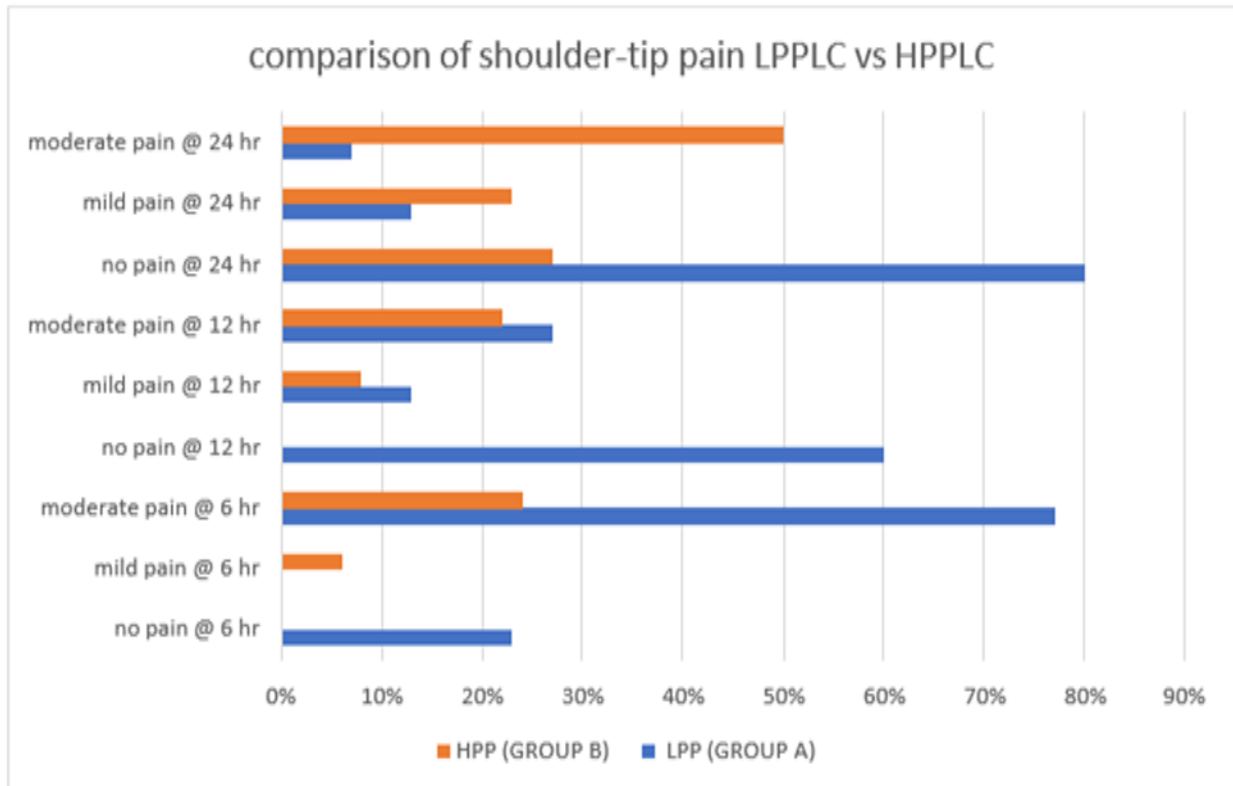


Figure 2: Comparison of post-op shoulder-tip pain in low-pressure pneumoperitoneum laparoscopic cholecystectomy (LPPLC) VS high-pressure pneumoperitoneum laparoscopic cholecystectomy (HPPLC)

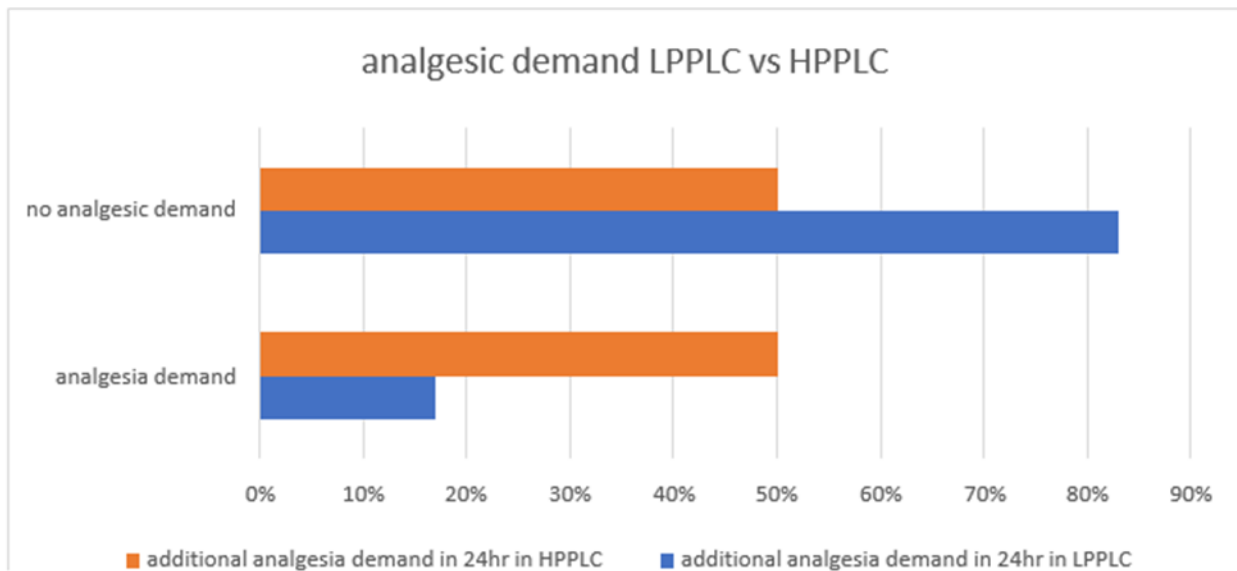


Figure 3: post-op additional analgesic demand in addition to 8 hourly doses in LPPLC vs HPPLC

Discussion

The fruits of laparoscopic surgery are reduced post-op pain, lesser morbidity to the upper abdomen related to incision, and early post-op recovery back to a normal lifestyle. Still, several patients experience post-op shoulder-tip pain. It is usually felt on the right or left shoulder and around the neck of the patient. Its pathophysiology is thought to be insufflated gas for pneumoperitoneum. The association of less post-op pain with low-pressure pneumoperitoneum is still controversial, according to some authors (Kandil and Hefnawy, 2010; Koc et al., 2005; Perrakis et al., 2003; Sandhu et al., 2009). Moreover, intra-operative use of suction for bleeding and bile spillage renders LPPLC difficult to perform, as suction causes more reduction in pneumoperitoneal pressure, compromising the vision of the operative field. But most studies (Donatsky et al., 2013; Gurusamy et al., 2014; Rosenthal et al., 1998; Sandoval-Jiménez et al., 2009) showed significantly reduced post-op shoulder-tip pain using low-pressure pneumoperitoneum. The result of our study also shows reduced post-op pain in low-pressure pneumoperitoneum. The recent trend in low-pressure pneumoperitoneum shows a lower impact on human physiology without affecting adequate working space (Rosenthal et al., 1998). With the advent of laparoscopic cholecystectomy and being designated the gold standard for its management. The aim has been to reduce trauma during minimally invasive surgery, increasing surgeon and patient satisfaction and decreasing operative difficulty (Chok et al., 2006). Due to pneumoperitoneum, raised intra-abdominal pressure causes several cardio-pulmonary changes, leading to increased absorption of carbon dioxide. It causes hypercapnia and acidosis, which can be managed by hyperventilation. It pushes the diaphragm superiorly in the expiration state, decreasing pulmonary compliance. These cardio-pulmonary changes may be tolerated by healthy individuals but people with cardio-pulmonary diseases have decreased cardiopulmonary reserve, it might not be tolerable for them.

To eliminate these issues, the idea of low-pressure pneumoperitoneum was introduced. Many researches have showed that low

pressure pneumoperitoneum is linked with better intra-operative tolerance, including anesthesia, and improved post-op recovery. Some authors reported that low-pressure pneumoperitoneum improves quality of life compared to high-pressure pneumoperitoneum cholecystectomy (Kanwer et al., 2010; Sarli et al., 2000; Wallace et al., 1997). Pain following pneumoperitoneum for laparoscopic cholecystectomy is related to several factors, such as tissue injury at port insertion sites and gall bladder bed, which are probably the most important contributing factors. The proposed causes of post-op shoulder pain are parietal peritoneum stretching, over-stretching of diaphragmatic musculature, and chemical irritation by carbon dioxide. In our study, post-op shoulder pain was low in low pneumoperitoneum pressure cholecystectomy. Differences were statistically significant at 6,12,24 hours. These findings followed Sarli L et al., who studied pain scores at 6 and 12 hours [8]. Sandhu T et al. observed a higher incidence of shoulder pain in the standard pressure group (Sandhu et al., 2009). Barczyński M Herman RM reported a 2.1 times lower incidence of shoulder pain after LPP than HPP (Barczyński and Herman, 2002).

Total analgesic demand was also reduced with LPP as compared to HPP. Thus, the intervention of reduced pneumoperitoneal pressure resulted in decreased incidence and severity of post-op shoulder pain and postoperative analgesia requirement.

Conclusion

This study concluded that low-pressure pneumoperitoneum reduces post-op shoulder pain intensity and post-op analgesia requirement with the benefit of shorter hospital stays. Considering these outcomes, the widespread use of low-pressure pneumoperitoneum (less than 10mHg) can be

used in laparoscopic cholecystectomy in un-complicated cases of cholelithiasis.

Declarations

Data Availability statement

All data generated or analyzed during the study are included in the manuscript.

Ethics approval and consent to participate.

Approved by the department concerned.

Consent for publication

Approved

Funding

Not applicable

Conflict of interest

The authors declared an absence of conflict of interest.

References

- Barczyński, M., and Herman, R. (2004). Low-pressure pneumoperitoneum combined with intraperitoneal saline washout for reduction of pain after laparoscopic cholecystectomy: a prospective randomized study. *Surgical Endoscopy and Other Interventional Techniques* 18, 1368-1373.
- Barczyński, M., and Herman, R. M. (2002). The usefulness of low-pressure pneumoperitoneum in laparoscopic surgery. *Folia Medica Cracoviensia* 43, 43-50.
- Chok, K. S., Yuen, W. K., Lau, H., and Fan, S. T. (2006). Prospective randomized trial on low-pressure versus standard-pressure pneumoperitoneum in outpatient laparoscopic cholecystectomy. *Surgical Laparoscopy Endoscopy & Percutaneous Techniques* 16, 383-386.
- Dexter, S., Vucevic, M., Gibson, J., and McMahon, M. (1995). Preservation of hemodynamic function by low pressure laparoscopic cholecystectomy. *Surg Endosc* 9, 600.
- Donatsky, A. M., Bjerrum, F., and Gögenur, I. (2013). Surgical techniques to minimize shoulder pain after laparoscopic cholecystectomy. A systematic review. *Surgical endoscopy* 27, 2275-2282.
- Gurusamy, K. S., Vaughan, J., and Davidson, B. R. (2014). Low pressure versus standard pressure pneumoperitoneum in laparoscopic cholecystectomy. *Cochrane Database of Systematic Reviews*.
- Haribhakti, S. P., and Mistry, J. H. (2015). Techniques of laparoscopic cholecystectomy: Nomenclature and selection. *Journal of minimal access surgery* 11, 113.
- Kandil, T. S., and Hefnawy, E. E. (2010). Shoulder pain following laparoscopic cholecystectomy: factors affecting the incidence and severity. *Journal of Laparoendoscopic & Advanced Surgical Techniques* 20, 677-682.
- Kanwer, D. B., Kaman, L., Nedounsejane, M., Medhi, B., Verma, G. R., and Bala, I. (2010). Comparative study of low pressure versus standard pressure pneumoperitoneum in laparoscopic cholecystectomy-a randomised controlled trial. *Tropical Gastroenterology* 30, 171-174.
- Koc, M., Ertan, T., Tez, M., Kocpinar, M. A., Kilic, M., Gocmen, E., and Aslar, A. K. (2005). Randomized, prospective comparison of postoperative pain in low-versus high-pressure pneumoperitoneum. *ANZ journal of surgery* 75, 693-696.
- McSherry, C. K. (1989). Cholecystectomy: the gold standard. *The American journal of surgery* 158, 174-178.
- Perrakis, E., Vezakis, A., Velimezis, G., Savanis, G., Deverakis, S., Antoniadis, J., and Saggkana, E. (2003). Randomized comparison between different insufflation pressures for laparoscopic cholecystectomy. *Surgical Laparoscopy Endoscopy & Percutaneous Techniques* 13, 245-249.
- Rosenthal, R. J., Friedman, R. L., Kahn, A. M., Martz, J., Thiagarajah, S., Cohen, D., Shi, Q., and Nussbaum, M. (1998). Reasons for intracranial hypertension and hemodynamic instability during acute elevations of intra-abdominal pressure: observations in a large animal model. *Journal of Gastrointestinal Surgery* 2, 415-425.
- Sandhu, T., Yamada, S., Ariyakachon, V., Chakrabandhu, T., Chongruksut, W., and Ko-Iam, W. (2009). Low-pressure pneumoperitoneum versus standard pneumoperitoneum in laparoscopic cholecystectomy, a prospective randomized clinical trial. *Surgical endoscopy* 23, 1044-1047.
- Sandoval-Jiménez, C., Méndez-Sashida, G., Cruz-Márquez-Rico, L., Cárdenas-Victorica, R., Guzmán-Esquivel, H., Luna-Silva, M., and Díaz-Valero, R. (2009). Postoperative pain in patients undergoing elective laparoscopic cholecystectomy with low versus standard-pressure pneumoperitoneum. A randomized clinical trial. *Revista de Gastroenterología de Mexico* 74, 314-320.
- Sarli, L., Costi, R., Sansebastiano, G., Trivelli, M., and Roncoroni, L. (2000). Prospective randomized trial of low-pressure pneumoperitoneum for reduction of shoulder-tip pain following laparoscopy. *Journal of British Surgery* 87, 1161-1165.
- Semm, K., and Riedel, H. (1980). Das postpelviskopische (laparoskopische) schmerzsyndrom. *Geburtshilfe Fraueheilk* 40, 635-643.
- Wallace, D., Serpell, M., Baxter, J., and O'dwyer, P. (1997). Randomized trial of different insufflation pressures for laparoscopic cholecystectomy. *British journal of surgery* 84, 455-458.



Open Access This article is licensed under a Creative Commons Attribution 4.0 International License, which permits use, sharing, adaptation, distribution and reproduction in any medium or format, as long as you give appropriate credit to the original author(s) and the source, provide a link to the Creative Commons licence, and indicate if changes were made. The images or other third party material in this article are included in the article's Creative Commons licence, unless indicated otherwise in a credit line to the material. If material is not included in the article's Creative Commons licence and your intended use is not permitted by statutory regulation or exceeds the permitted use, you will need to obtain permission directly from the copyright holder. To view a copy of this licence, visit <http://creativecommons.org/licenses/by/4.0/>. © The Author(s) 2023