

## FREQUENCY OF LEFT VENTRICULAR THROMBUS IN PATIENTS WITH ACUTE ANTERIOR WALL MYOCARDIAL INFARCTION

SAJJAD M<sup>\*1</sup>, ULLAH N<sup>2</sup>, QURESHI AE<sup>2</sup>, ANUM H<sup>2</sup>, FAROOQ U<sup>2</sup>, DAR WA<sup>3</sup>

<sup>1</sup>Department of cardiology, Gulab Devi Hospital Lahore, Pakistan

<sup>2</sup>Department of cardiology, Rehmatul-lil-Alamen institute of cardiology, PESSI, Lahore, Pakistan

<sup>3</sup> Department of Cardiology, Punjab cardiac and medical center Ravi Road Lahore, Pakistan

\*Correspondence author email address: [mehrozajjad@hotmail.com](mailto:mehrozajjad@hotmail.com)

(Received, 19<sup>th</sup> October 2022, Revised 29<sup>th</sup> January 2023, Published 10<sup>th</sup> April 2023)

**Abstract:** Acute myocardial infarction (AMI) can be fatal and, if not, can result in many short- and long-term complications. Left ventricular thrombus (LVT) is an underrated complication that can lead to systemic embolization and, ultimately, stroke or end-organ damage. The current cross-sectional study is designed to determine the frequency of left ventricular thrombus after acute anterior wall myocardial infarction at the Department of Cardiology, Rehmatul-lil-Alameen Institute of Cardiology, Lahore, from 12-09-2020 to 11-03-2021. All patients of 20 to 60 years of either gender meeting the operational definition of the acute anterior wall were included. LV thrombus was diagnosed on echocardiography as an amorphous echogenic structure with variable shape and adherent to the endocardium. In this study, there were 87 cases; out of these, there were 57 (65.52%) males, and 30 (34.48%) females. The mean age of the subjects was 49.90±6.27 years. Out of 87 cases, 37 (42.53%) had a history of DM, 30 (45.98%) were hypertensive, and 31 (35.63%) were smokers. Left ventricular thrombus (LVT) was found in 16 (18.39%) cases. LVT was seen in 9 (15.79%) males vs. 7 (23.33%) females with  $p=0.39$ . LVT was seen in 5 (13.51%) cases with DM and 11 (22%) with no DM, 7 (17.50%) cases with HTN, and 9 (19.15%) normotensives with  $p=0.41$  and 1.0. LVT was found in 5 (22.72%) cases with ejection fraction (EF) up to 40% and 11 (16.92%) cases with EF more than this with  $p=0.18$ . Based on the results, the left ventricular thrombus is not uncommon after acute anterior wall MI and is nearly seen in every one out of five cases and is more common in cases with ejection fraction up to 40%.

**Keywords:** Myocardial infarction, Left ventricular thrombus, Echocardiography, Ejection fraction, Anterior wall MI

### Introduction

Acute anterior wall myocardial infarction (MI) is a potentially life-threatening condition that requires prompt and appropriate management (Singh et al., 2021). One of the possible complications of this condition is the formation of a blood clot in the heart's left ventricle, known as a left ventricular thrombus (LVT) (Magdás et al., 2021). LVTs can cause serious complications, including embolic stroke, peripheral arterial embolization, and pulmonary embolism. Therefore, detecting and managing LVTs in patients with acute anterior wall MI is critical for improving outcomes and reducing the risk of complications (Lai et al., 2019). The frequency of LVTs in patients with acute anterior wall MI has been reported in several studies. According to a meta-analysis of 31 studies, the overall frequency of LVTs in patients with acute MI was 13.6%, with a higher prevalence in patients with anterior wall MI (19.7%) than those with inferior wall MI (6.6%) (Costa et al., 2001). Another study found that the prevalence of LVTs in patients with acute anterior wall MI was 26%, and the presence of

LVTs was associated with a higher risk of stroke and mortality (Solheim et al., 2010). A systematic review and meta-analysis of 11 studies also reported a higher frequency of LVTs in patients with anterior wall MI (24.3%) compared to those with inferior wall MI (3.3%) (Orimoloye et al., 2018).

The frequency of LVTs in patients with acute anterior wall MI appears to vary depending on several factors, including the patient population, the imaging modality used, and the timing of the assessment. For example, a study that evaluated the frequency of LVTs using transthoracic echocardiography (TTE) within 24 hours of admission reported a lower prevalence of LVTs (9.6%) in patients with anterior wall MI (Weinsaft et al., 2011). In contrast, a study that used cardiac magnetic resonance imaging (MRI) for LVT detection reported a higher prevalence of LVTs (43%) in patients with acute anterior wall MI (Cohen et al., 2021). Therefore, the choice of imaging modality and timing of assessment may affect the frequency of LVTs reported in different studies.

Several risk factors for forming LVTs in patients with acute anterior wall MI have been identified. These include advanced age, female sex, previous MI, heart failure, diabetes, hypertension, and larger infarct size (Chamoun et al., 2003). These risk factors may increase the likelihood of LVT formation and the associated risk of complications. Myocardial infarction (MI) is typically the result of an imbalance in oxygen supply and demand, most commonly caused by plaque rupture with thrombus formation in an epicardial coronary artery. This results in an acute reduction of blood supply to a portion of the myocardium. Myocardial infarction is also a heart attack (Al-Khatib et al., 2018).

The detection and management of left ventricular thrombus (LVT) in patients with acute anterior wall myocardial infarction (MI) are crucial for improving outcomes and reducing the risk of complications. In this context, identifying the frequency of LVTs in this patient population can help inform clinical decision-making and guide appropriate interventions (Olsen et al., 2020).

The formation of LVTs in patients with acute anterior wall MI is thought to be related to a range of factors, including decreased left ventricular function, blood stasis, and increased blood coagulability. These factors can contribute to the formation of a blood clot in the heart's left ventricle, leading to a range of serious complications, including embolic stroke, peripheral arterial embolization, and pulmonary embolism. Therefore, detecting and managing LVTs in these patients is critical for preventing these complications and improving outcomes (Saric et al., 2016). Thus, the current cross-sectional study is designed to determine the frequency of left ventricular thrombus after acute anterior wall myocardial infarction (Park et al., 2015).

## Methodology

The current cross-sectional analysis was conducted at the Department of Cardiology, Rehmatul -lil-Alameen Institute of Cardiology, Lahore, from 12-09-2020 to 11-03-2021.

A sample size of 87 was calculated using the WHO sample size calculator. The expected prevalence of left ventricular thrombus after acute anterior wall myocardial infarction was 34.1% (P), with a 95% confidence level and 10% absolute precision (Mostofsky et al., 2012). Non-probability consecutive sampling techniques were applied to collect the data. All patients of 20 to 60 years of either gender meeting the operational definition of acute anterior wall suggested by clinical history and ECG changes according to the operational definition were included in the study. In contrast, patients with rheumatic heart disease or dilated cardiomyopathy detected on

echocardiogram, old inferior wall MI with current anterior wall MI, known case of valvular heart disease, acute pericarditis, myocarditis, with a previous history of mural thrombus or systemic thrombo-embolism and patients with other comorbidities like End stage renal disease (eGFR < 15 mL/min or need for transplant or dialysis) and Chronic liver disease (Child-Pugh Class B and C) were excluded from the study.

After the approval to carry out this study from the Ethical Review Committee, 87 subjects meeting the operational definitions and the inclusion criteria were enrolled in the study after informed consent from the patients.

A detailed history of the patients was taken. Echocardiography was performed on every patient immediately post-infarct to detect left ventricular thrombus. History of diabetes mellitus (DM), hypertension (HTN), smoking, family history of premature coronary artery disease (CAD) and duration of chest pain and ECG diagnosis of STEMI along with management, i.e., thrombolysis with fibrinolytic therapy or not, and ejection fraction were noted.

The data was analyzed using SPSS version 20. Frequency and percentages were calculated for qualitative variables, including gender and left ventricular thrombus, as per the operational definition. History of smoking, diabetes mellitus (DM), hypertension (HTN), ECG appearance. For the quantitative variables like age, and time between the onset of chest pain and ECG diagnosis of MI, mean  $\pm$ SD will be calculated. Effect modifiers like age, gender, history of smoking, diabetes mellitus (Fasting blood glucose  $\geq$  126 mg/dl or 2-hour plasma glucose of  $\geq$  200 mg/dl during a 75 gm oral glucose tolerance test), hypertension (Systolic blood pressure  $\geq$  120 mmHg and Diastolic blood pressure  $\geq$  80 mmHg, treated hypertension or history of pregnancy-induced hypertension in women) and family history of premature coronary artery disease (CAD in < 55 years in men, < 65 years in women) and ejection fraction were stratified to find out the effect of these on the outcome, through chi-square ( $p < 0.05$  was considered significant).

## Results

In this study, there was a total of 87 cases, and out of these, there were 57 (65.52%) males and 30 (34.48%) females (figure 1). Out of 87 cases, 37 (42.53%) had a history of DM, 30 (45.98%) were hypertensive, and 31 (35.63%) were smokers (figures 05-07). A family history of premature cardiac disease was seen in 20 (22.99%) of cases.

Left ventricular thrombus (LVT) was found in 16 (18.39%) cases, as shown in figure 2

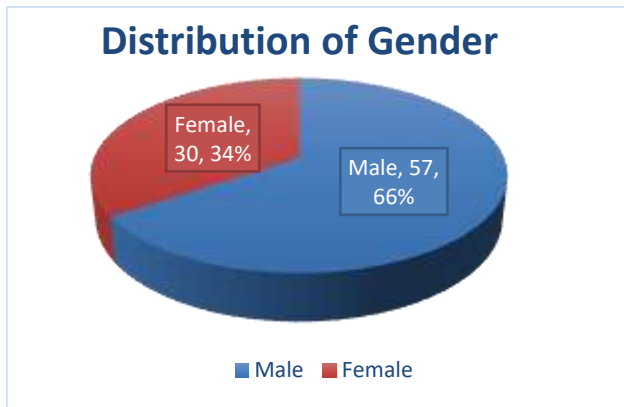


Figure 1 Distribution of gender

Table 1 Age and time of onset

Variables	Mini mum	Maxi mum	Mean	Std. Deviation
Age (years)	34	60	49.90	6.27
Time of onset (hrs.)	1	14	7.79	2.31

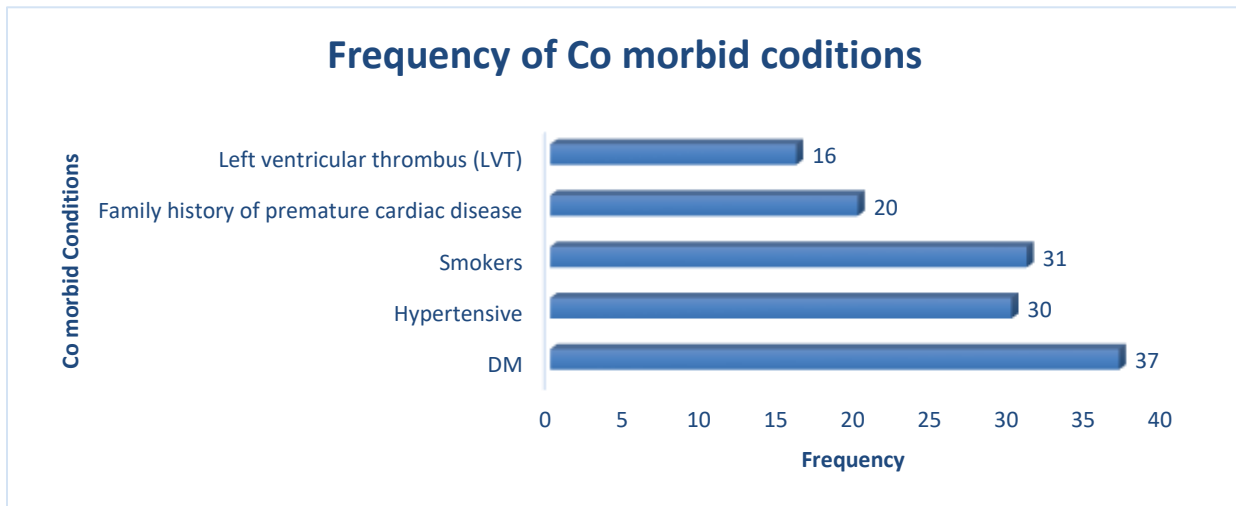


Figure 2 Frequency of comorbid conditions in the study group

Table 2 Association of LVT with different variables

Variables	Constructs	LVT		P- Value
		Yes	No	
<b>GENDER</b>	<b>Male</b>	9 (15.79%)	48 (84.21%)	<b>0.39</b>
	<b>Female</b>	7 (23.33%)	23 (76.67%)	
<b>AGE (Years)</b>	<b>20-39</b>	2 (22.22%)	7 (77.78%)	<b>0.67</b>
	<b>40-60</b>	14 (17.94%)	64 (82.06%)	
<b>DM</b>	<b>Yes</b>	5 (13.51%)	32 (86.49%)	<b>0.41</b>
	<b>No</b>	11 (22%)	39 (78%)	
<b>HTN</b>	<b>Yes</b>	7 (17.50%)	33 (82.50%)	<b>0.10</b>
	<b>No</b>	9 (19.15%)	38 (80.85%)	
<b>Smoking</b>	<b>Yes</b>	5 (16.13%)	26 (83.87%)	<b>0.78</b>
	<b>No</b>	11 (19.64%)	45 (80.36%)	
<b>Family h/o CAD</b>	<b>Yes</b>	4 (20%)	16 (80%)	<b>0.10</b>
	<b>No</b>	12 (17.91%)	55 (82.09%)	
<b>Ejection Fraction</b>	<b>Upto 40</b>	5 (22.72%)	17 (77.28%)	<b>0.18</b>
	<b>&gt;40</b>	11 (16.92%)	54 (83.08%)	

[Citation: Sajjad, M., Ullah, N., Qureshi, A.E, Anum, H., Farooq, U., Dar, W.A. (2023). Frequency of left ventricular thrombus in patients with acute anterior wall myocardial infarction. *Biol. Clin. Sci. Res. J.*, 2023: 234. doi: <https://doi.org/10.54112/bcsrj.v2023i1.234>]

LVT was seen in 9 (15.79%) males vs. 7 (23.33%) females with  $p= 0.39$ . There was no significant difference in terms of age, with  $p= 0.67$ . LVT was seen in 5 (13.51%) cases with DM and 11 (22%) with no DM, 7 (17.50%) cases with HTN, and 9 (19.15%) normotensives with  $p= 0.41$  and 1.0, respectively. There was no significant association of LVT with smoking and family history of CAD. LVT was found in 5 (22.72%) cases with EF up to 40% and 11 (16.92%) cases with EF more than this with  $p= 0.18$ , as displayed in table 2.

## Discussion

Acute Myocardial infarction (AMI) is the leading cause of death worldwide, with significant morbidity in all hospitalized patients. The average mortality rate of acute myocardial infarction is even  $>30\%$ . However, with the evolution in treatment strategies, morbidity and mortality have decreased through the improvement of the coronary unit, fibrinolytic therapy, and catheter-based revascularization, but still, the situation is worsening with time (Vogel et al., 2019).

Left ventricular thrombus (LVT) formation is a common complication of acute MI. Its incidence is between 20-50%, with large anterior wall MI. Pathophysiology of left ventricular thrombus formation can be explained by "Virchow's triad," i.e., stasis of blood, endocardial injury or dysfunction, and a hyper-coagulable state. LV thrombus usually develops within one to two weeks of AMI (Camaj et al., 2022).

Transthoracic echocardiography (TTE) is the most commonly used imaging modality to diagnose left ventricular thrombus and has a sensitivity of 90%-95% and specificity of 85%-90% (Delewi et al., 2012). Management of LVT in the 21st century is primarily based on studies and the use of potent pharmacological and interventional therapies such as systemic anticoagulation and follow-up echocardiography (Habash and Vallurupalli, 2017).

Risk factors for developing LV thrombus include large infarct sizes, severe apical asynergy, left ventricle aneurysm and anterior wall myocardial infarction, reduced ejection fraction, and severe mitral regurgitation (Delewi et al., 2012).

The present study found left ventricular thrombus (LVT) in 16 (18.39%) cases. The data in the past regarding the prevalence of this was variable across the globe. The major confounders studied in the past were duration of infarction, difference in inclusion criteria and operational definitions, types of myocardial infarction, and mode of management in such cases.

A study by Iqbal MW et al. reported LVT in 28% of AMI patients on trans thoracic echocardiography with significantly less incidence in the thrombolytic group

versus the non-thrombolytic group, i.e.,  $p$ -value  $<0.05$ . Furthermore, they revealed that thrombus formation was independent of age and gender, and similar was seen in the present study where LVT was seen in 9 (15.79%) males vs. 7 (23.33%) females with  $p= 0.39$  and also there was no significant difference in terms of age with  $p= 0.67$  (Iqbal et al., 2014).

In this study, LVT was more seen in cases with low ejection fraction, where this was found in 5 (22.72%) cases with EF up to 40% and 11 (16.92%) cases with EF more than this with  $p= 0.18$ . This was also in line with the findings of previous studies where the incidence of LVT was also higher in patients with an ejection fraction  $\leq 40\%$ ,  $p < 0.0001$ ). In patients with an anterior AMI and an ejection fraction  $\leq 40\%$ , this percentage was as high as 17.8% (Rosamond et al., 2007).

Another study by Jalal-ud-din M et al. reported. Included 85 patients, and the frequency of LVT was seen as high as 34.1%. This was much higher as compared to the present study, and the reason for this was explained by the factor that in their study, only cases suffering from acute anterior wall MI were included, which has shown a direct association with a higher risk of LV thrombus formation as compared to other forms of MI which were also entertained in present study (Jadoon et al., 2014).

According to another study by Porter et al., LVT in 23.5% of the patients suffering from acute anterior wall MI developed LVT, while this incidence was 42.8%, as shown in the results of another study done by Okuyan et al. in Turkey with similar inclusion criteria. However, compared to them, the results were lower in Porter's study, which can be explained by the availability of early reperfusion therapies, which was not analyzed in the present study (Okuyan et al., 2010).

In Pakistan, there was also variable data, and according to two studies conducted two different studies on anterior wall MI and the incidence was similar (26.66%) (CHAUDHRY et al., 2004). In contrast, Rathi and his colleagues, who didn't restrict their study to anterior wall MI as was done in the present study, found that 17.8% of the patient of all MI groups developed LV Thrombus. In their study, out of 138 anterior wall MI patients, 45 (32.6%) developed LV Thrombus. These results were comparable with our results (Rathi et al., 2009).

Rehan et al. (11%) and Kalra et al. (10%) further reduced the incidence of LV Thrombus. This reduced incidence was reported to be due to early treatment by primary PCI in these patients (Rehan et al., 2006). Kambery et al., in a recent study, concluded that in patients in whom PCI was administered as the primary therapy, the frequency of LVT was 5.6% in anterior MI, while in the non-PCI group, the frequency was as high as 44.4% (Kamperi et al., 2011).

This study had a few limitations as it didn't look for types of myocardial infarction as confabulation to look for its association with LV thrombus. Also, management options were not assessed, i.e., the cases managed with conventional thrombolytic therapies or percutaneous interventions, i.e., angioplasty. However, there were many strengthening points, and this study highlighted an underrated complication and assessed it against several confounding variables.

## Conclusion

Left ventricular thrombus is common after acute anterior wall MI and is nearly seen in every one out of five cases and is more common in cases with ejection fraction up to 40%.

## Conflict of interest

The authors declared an absence of conflict of interest.

## References

- Al-Khatib, S. M., Stevenson, W. G., Ackerman, M. J., Bryant, W. J., Callans, D. J., Curtis, A. B., Deal, B. J., Dickfeld, T., Field, M. E., and Fonarow, G. C. (2018). 2017 AHA/ACC/HRS guideline for management of patients with ventricular arrhythmias and the prevention of sudden cardiac death: a report of the American College of Cardiology/American Heart Association Task Force on Clinical Practice Guidelines and the Heart Rhythm Society. *Journal of the American College of Cardiology* **72**, e91-e220.
- Camaj, A., Fuster, V., Giustino, G., Bienstock, S. W., Sternheim, D., Mehran, R., Dangas, G. D., Kini, A., Sharma, S. K., and Halperin, J. (2022). Left ventricular thrombus following acute myocardial infarction: JACC state-of-the-art review. *Journal of the American College of Cardiology* **79**, 1010-1022.
- Chamoun, A. J., McCulloch, M., Xie, T., Shah, S., and Ahmad, M. (2003). Real-Time three-dimensional echocardiography versus two-dimensional echocardiography in the diagnosis of left ventricular apical thrombi: Preliminary findings. *Journal of clinical ultrasound* **31**, 412-418.
- CHAUDHRY, A. H., Nagra, H., AMIN, K., Kafeel, I., and SHAOUKAT, A. (2004). ACUTE ANTERIOR MYOCARDIAL INFARCTION: THE INCIDENCE OF LEFT VENTRICULAR THROMBUS. *The Professional Medical Journal* **11**, 57-62.
- Cohen, A., Donal, E., Delgado, V., Pepi, M., Tsang, T., Gerber, B., Soulat-Dufour, L., Habib, G., Lancellotti, P., and Evangelista, A. (2021). EACVI recommendations on cardiovascular imaging for the detection of embolic sources: endorsed by the Canadian Society of Echocardiography. *European Heart Journal-Cardiovascular Imaging* **22**, e24-e57.
- Costa, M., Grant, P. J., Rice, G. I., Futers, S. T., and Medcalf, R. L. (2001). Human endothelial cell-derived nuclear proteins that recognise polymorphic DNA elements in the von Willebrand factor gene promoter include YY1. *Thrombosis and haemostasis* **86**, 672-679.
- Delewi, R., Zijlstra, F., and Piek, J. J. (2012). Left ventricular thrombus formation after acute myocardial infarction. *Heart* **98**, 1743-1749.
- Habash, F., and Vallurupalli, S. (2017). Challenges in management of left ventricular thrombus. *Therapeutic advances in cardiovascular disease* **11**, 203-213.
- Iqbal, M. W., Fayyaz, A., and Hanif, A. (2014). Frequency of left ventricular thrombus after anterior wall ST-segment elevation acute Myocardial infarction. *Annals of King Edward Medical University* **20**, 68-68.
- Jadoon, R. J., Qureshi, A., Khan, S. A., Anwar, S. A., and Haroon, M. Z. (2014). Left ventricular thrombus in patients with acute anterior wall myocardial infarction. *Journal of Ayub Medical College Abbottabad* **26**, 491-5.
- Kamberi, L. S., Karabulut, A. M., Çitaku, H. R., Gorani, D. R., and Beqiri, A. I. (2011). Incidence of early Left ventricular thrombus and stroke after acute Myocardial infarction in the Primary coronary Intervention era compared to conservative treatment. *Acta Informatica Medica* **19**, 88.
- Lai, E., Alishetti, S., Wong, J., Delic, L., Rosenblatt, A., and Egrie, G. (2019). Right ventricular thrombus in transit: raising the stakes in the management of pulmonary embolism. *Journal of the American College of Cardiology* **73**, 2844-2844.
- Magdás, A., Podoleanu, C., and Frigy, A. (2021). Extensive Left Ventricular Thrombosis with Concomitant Pulmonary Embolism. *Clinics and Practice* **11**, 303-308.
- Mostofsky, E., Maclure, M., Sherwood, J. B., Tofler, G. H., Muller, J. E., and Mittleman, M. A. (2012). Risk of acute myocardial infarction after the death of a significant person in one's life: the Determinants of Myocardial Infarction Onset Study. *Circulation* **125**, 491-496.
- Okuyan, E., Okcun, B., Dinçkal, M. H., and Mutlu, H. (2010). Risk factors for development of left ventricular thrombus after first acute anterior

- myocardial infarction-association with anticardiolipin antibodies. *Thrombosis journal* **8**, 1-7.
- Olsen, F. J., Pedersen, S., Galatius, S., Fritz-Hansen, T., Gislason, G., and Biering-Sørensen, T. (2020). Association between regional longitudinal strain and left ventricular thrombus formation following acute myocardial infarction. *The international journal of cardiovascular imaging* **36**, 1271-1281.
- Orimoloye, O. A., Budoff, M. J., Dardari, Z. A., Mirbolouk, M., Uddin, S. I., Berman, D. S., Rozanski, A., Shaw, L. J., Rumberger, J. A., and Nasir, K. (2018). Race/ethnicity and the prognostic implications of coronary artery calcium for all-cause and cardiovascular disease mortality: the coronary artery calcium consortium. *Journal of the American Heart Association* **7**, e010471.
- Rathi, N. L., RK, S., and NA, M. (2009). Left ventricular thrombus in acute myocardial infarction. *Pakistan Heart Journal* **42**.
- Rehan, A., Kanwar, M., Rosman, H., Ahmed, S., Ali, A., Gardin, J., and Cohen, G. (2006). Incidence of post myocardial infarction left ventricular thrombus formation in the era of primary percutaneous intervention and glycoprotein IIb/IIIa inhibitors. A prospective observational study. *Cardiovascular ultrasound* **4**, 1-5.
- Rosamond, W., Flegal, K., Friday, G., Furie, K., Go, A., Greenlund, K., Haase, N., Ho, M., Howard, V., and Kissela, B. (2007). Heart disease and stroke statistics—2007 update: a report from the American Heart Association Statistics Committee and Stroke Statistics Subcommittee. *Circulation* **115**, e69-e171.
- Saric, M., Armour, A. C., Arnaout, M. S., Chaudhry, F. A., Grimm, R. A., Kronzon, I., Landeck, B. F., Maganti, K., Michelena, H. I., and Tolstrup, K. (2016). Guidelines for the use of echocardiography in the evaluation of a cardiac source of embolism. *Journal of the American Society of Echocardiography* **29**, 1-42.
- Singh, A. P., Kayal, V., and Nath, R. K. (2021). Aortic Dissection With Complete Occlusion of Left Main Coronary Artery Presenting as Acute ST-Segment Elevation Myocardial Infarction. *Cureus* **13**.
- Solheim, S., Seljeflot, I., Lunde, K., Bjørnerheim, R., Aakhus, S., Forfang, K., and Arnesen, H. (2010). Frequency of left ventricular thrombus in patients with anterior wall acute myocardial infarction treated with percutaneous coronary intervention and dual antiplatelet therapy. *The American journal of cardiology* **106**, 1197-1200.
- Vogel, B., Claessen, B. E., Arnold, S. V., Chan, D., Cohen, D. J., Giannitsis, E., Gibson, C. M., Goto, S., Katus, H. A., and Kerneis, M. (2019). ST-segment elevation myocardial infarction. *Nature reviews Disease primers* **5**, 39.
- Weinsaft, J. W., Kim, H. W., Crowley, A. L., Klem, I., Shenoy, C., Van Assche, L., Brosnan, R., Shah, D. J., Velazquez, E. J., and Parker, M. (2011). LV thrombus detection by routine echocardiography: insights into performance characteristics using delayed enhancement CMR. *JACC: Cardiovascular Imaging* **4**, 702-712.



**Open Access** This article is licensed under a Creative Commons Attribution 4.0 International License, which permits use, sharing, adaptation, distribution and reproduction in any medium or format, as long as you give appropriate credit to the original author(s) and the source, provide a link to the Creative Commons licence, and indicate if changes were made. The images or other third party material in this article are included in the article's Creative Commons licence, unless indicated otherwise in a credit line to the material. If material is not included in the article's Creative Commons licence and your intended use is not permitted by statutory regulation or exceeds the permitted use, you will need to obtain permission directly from the copyright holder. To view a copy of this licence, visit <http://creativecommons.org/licenses/by/4.0/>.  
© The Author(s) 2023