

Comparison of Outcomes of Incision and Drainage vs Needle Aspiration of Breast Abscess

Narmeena Fakhar*, Imran Aslam, Sajeel Ahmed, Akasha Adnan, Ali Akbar

Department of Surgery, Sir Ganga Ram Hospital, Lahore, Pakistan

*Corresponding author's email address: narmeenafakhar7@gmail.com

(Received, 4th June 2025, Accepted 15th July 2025, Published 31st July 2025)

Abstract: Lactational breast abscess is a common complication of breastfeeding, often resulting in pain, interrupted lactation, and potential morbidity. Standard management includes incision and drainage (I&D) or ultrasound-guided needle aspiration (USGNA), with varying outcomes reported in the literature. **Objective:** To compare the clinical outcomes of I&D versus USGNA in patients with lactational breast abscess. **Methods:** A randomized controlled trial was conducted at the Department of General Surgery, Sir Ganga Ram Hospital, Lahore, over six months from 16 November 2024 to 16 May 2025. A total of 68 lactating women with first-time breast abscesses measuring 2–10 cm was enrolled and randomly assigned to USGNA (n=34) or I&D (n=34). All patients received broad-spectrum antibiotics post-procedure, adjusted according to pus culture and sensitivity. Primary outcome was complete resolution of abscess at four weeks. Secondary outcomes included pain score, time to breastfeeding resumption, cosmetic satisfaction, and need for repeat aspiration. Data were analysed using SPSS version 25; categorical variables were compared using Chi-square test, and continuous variables using independent t-test, with $p \leq 0.05$ considered significant. **Results:** Complete resolution was observed in 30 (88.2%) patients in the USGNA group and 33 (97.1%) in the I&D group ($p = 0.18$). USGNA patients experienced significantly lower pain scores (3.1 ± 0.9 vs. 6.4 ± 1.2 , $p < 0.001$), faster resumption of breastfeeding (1.2 ± 0.5 vs. 3.8 ± 1.1 days, $p < 0.001$), and higher cosmetic satisfaction (8.7 ± 0.8 vs. 7.2 ± 1.0 , $p < 0.001$). Repeat aspiration was required in 2 (6%) USGNA patients, while none in the I&D group needed additional intervention. **Conclusion:** Both I&D and USGNA are effective in treating lactational breast abscess. USGNA provides the advantages of reduced pain, better cosmetic outcomes, and earlier breastfeeding, making it a feasible outpatient alternative for unilocular abscesses. I&D remains preferred for multiloculated or large abscesses due to slightly higher resolution rates.

Keywords: Lactational Breast Abscess, Needle Aspiration, Incision and Drainage, Breastfeeding, Ultrasonography

[**How to Cite:** Fakhar N, Aslam I, Ahmed S, Adnan A, Akbar A. Comparison of outcomes of incision and drainage vs needle aspiration of breast abscess. *Biol. Clin. Sci. Res. J.*, 2025; 6(7): 129-131. doi: <https://doi.org/10.54112/bcsrj.v6i7.2294>]

Introduction

Women are susceptible to a variety of breast problems during pregnancy and lactation, ranging from mild conditions such as sore nipples, mastitis, and galactoceles to more severe complications like breast abscess and malignancy (1). Among these, lactational breast abscess is a common and significant problem, defined as a localized collection of pus within the breast tissue of a lactating woman. This condition can lead to considerable morbidity, affecting up to 11% of lactating women (2). The incidence is particularly high among primiparous women, estimated at 85%, largely due to insufficient knowledge regarding proper breastfeeding techniques and nipple hygiene (3). The first six months postpartum are considered the highest risk period for developing a lactational breast abscess (4).

Several predisposing factors contribute to the development of lactational breast abscess. These include increasing maternal age, post-term pregnancy, cracked nipples, and prior episodes of mastitis (5). Occupational demands that limit time for proper breastfeeding practices also increase the risk. Additionally, maternal smoking can lead to milk stasis, which promotes bacterial growth and subsequent abscess formation. Clinically, patients present with painful, swollen, and erythematous breasts, often accompanied by fever and reduced milk flow (6). On examination, the affected breast typically shows a fluctuant swelling, and enlarged, tender axillary lymph nodes may also be observed. While diagnosis can often be made clinically, ultrasonography is recommended to confirm the presence of pus collection, evaluate abscess size, and exclude complex or septated lesions. Pus samples are usually sent for culture and sensitivity to guide appropriate antibiotic therapy (7).

Management strategies for lactational breast abscess include incision and drainage (I&D) or ultrasound-guided needle aspiration (USGNA), in combination with antibiotics. Incision and drainage are traditionally


considered the standard treatment and is highly effective in achieving complete resolution due to thorough loculi disruption. However, it requires anesthesia, hospitalization, daily wound care, and may delay breastfeeding due to pain and wound discomfort (8). In contrast, USGNA is an outpatient procedure that is less painful, promotes early resumption of breastfeeding, and provides better cosmetic results. Nevertheless, multiple aspirations may be necessary in some cases (9).

Studies have reported variable success rates for these interventions. Complete resolution was achieved in 89.66% of patients treated with USGNA and 93.33% with incision and drainage. These variations suggest that local validation of outcomes is necessary to determine the optimal management approach in specific populations. Therefore, this study aims to compare the clinical outcomes of incision and drainage versus needle aspiration of breast abscess in patients presenting to a tertiary care hospital.

Methodology

This study is a randomized controlled trial conducted to compare the outcomes of incision and drainage (I&D) versus ultrasound-guided needle aspiration (USGNA) in patients with lactational breast abscess. The study was carried out in the Department of General Surgery at Sir Ganga Ram Hospital, Lahore, a tertiary care teaching hospital, over a period of six months from 16 November 2024 to 16 May 2025, following approval from the hospital Ethical Review Board.

A total of 68 patients were included in the study, with 34 patients assigned to each treatment group. The sample size was calculated using a 95% confidence level and 90% power, based on previous literature reporting complete resolution rates of 70% for USGNA and 100% for I&D. Patients were recruited consecutively using a non-probability sampling technique until the desired sample size was achieved.



Women aged 18 to 45 years, presenting with a first-time lactational breast abscess measuring 2–10 cm on ultrasonography with no internal septations, were considered eligible for inclusion. Patients with a history of antibiotic therapy for the current abscess, recurrent or non-lactational breast abscess, or uncontrolled diabetes mellitus were excluded from the study.

After obtaining written informed consent, participants were randomly allocated to either the USGNA group or the I&D group using a lottery method. Patients in the USGNA group underwent wide-bore needle aspiration using a 14G cannula under ultrasound guidance, with repeat aspirations performed if necessary. Patients in the I&D group underwent conventional incision and drainage under local or general anesthesia, depending on abscess size and patient preference. Pus samples were collected at the time of the procedure for culture and sensitivity, and all patients received broad-spectrum antibiotics immediately post-procedure, which were adjusted according to laboratory results.

Demographic data, including age, parity, and body mass index, were recorded for all patients. Participants were followed up for four weeks to assess the primary outcome of complete resolution of the breast abscess. Secondary outcomes, such as pain, requirement for repeat intervention, breastfeeding interruption, and cosmetic outcomes, were also monitored. All data were documented using a standardized proforma.

Data analysis was performed using SPSS version 25. Continuous variables, such as age and BMI, were expressed as mean ± standard deviation, while categorical variables, including parity and abscess resolution, were presented as frequencies and percentages. Data were stratified for age, BMI, and parity, and post-stratification analysis was conducted using the Chi-square test. A p-value of ≤0.05 was considered statistically significant.

Ethical considerations were strictly adhered to, with patient confidentiality maintained throughout the study and written informed consent obtained from all participants.

Results

A total of 68 patients with lactational breast abscess were enrolled in the study, with 34 patients in the USGNA group and 34 in the I&D group. The mean age of patients in the USGNA group was 28.9 ± 4.2 years, and in the I&D group, it was 29.5 ± 4.0 years (p = 0.48). The mean body mass index (BMI) was 26.1 ± 2.8 kg/m² in the USGNA group and 26.4 ± 3.1 kg/m² in the I&D group (p = 0.62). Parity distribution was comparable between the two groups (p = 0.74) in Table 1.

Table 1: Baseline Characteristics of Study Participants

Variable	USGNA (n=34)	I&D (n=34)	p-value
Age (years)	28.9 ± 4.2	29.5 ± 4.0	0.48
BMI (kg/m ²)	26.1 ± 2.8	26.4 ± 3.1	0.62
Primiparous (%)	20 (58.8%)	18 (52.9%)	0.74
Multiparous (%)	14 (41.2%)	16 (47.1%)	

Table 2: Secondary Outcomes

Variable	USGNA (n=34)	I&D (n=34)	p-value
Time to breastfeeding (days)	1.2 ± 0.5	3.8 ± 1.1	<0.001
Pain score (VAS, 24h)	3.1 ± 0.9	6.4 ± 1.2	<0.001
Cosmetic satisfaction (VAS)	8.7 ± 0.8	7.2 ± 1.0	<0.001

Secondary outcomes were also analysed. The mean time to breastfeeding resumption was significantly shorter in the USGNA group (1.2 ± 0.5 days) compared to the I&D group (3.8 ± 1.1 days, p < 0.001). Patients in the USGNA group reported lower pain scores on a visual analog scale (VAS) at 24 hours post-procedure (3.1 ± 0.9) compared to the I&D group (6.4 ± 1.2, p < 0.001). Cosmetic satisfaction, assessed at 4 weeks, was higher in the USGNA group (VAS 8.7 ± 0.8) than in the I&D group (VAS 7.2 ± 1.0, p < 0.001) in Table 2.

The primary outcome, complete resolution of breast abscess at 4 weeks, was achieved in 30 patients (88.2%) in the USGNA group and 33 patients (97.1%) in the I&D group. Although I&D showed a slightly higher resolution rate, the difference was not statistically significant (p = 0.18) in fig 1.

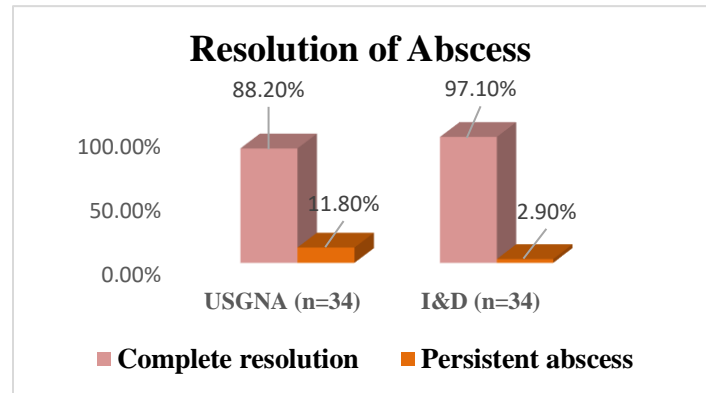


Figure 1. Primary Outcome Complete Resolution of Abscess

Overall, both USGNA and I&D were effective in achieving resolution of lactational breast abscess. However, USGNA offered advantages in terms of faster resumption of breastfeeding, reduced pain, and better cosmetic outcomes, whereas I&D had slightly higher, though not statistically significant, complete resolution rates.

Discussion

In this randomized controlled trial, we compared the outcomes of incision and drainage (I&D) versus ultrasound-guided needle aspiration (USGNA) in patients with lactational breast abscess. Both interventions were effective in achieving complete resolution of abscesses, with I&D showing slightly higher resolution rates 97.1% compared to USGNA 88.2%. Although this difference was not statistically significant (p = 0.18), it aligns with previous literature reporting high efficacy of both procedures (9, 10).

The complete resolution rate in the USGNA group in our study (88.2%) is consistent with prior studies that reported success rates ranging from 70% to 89.7%. This variation may be attributed to differences in patient selection, abscess size, and the number of aspirations performed (11, 12). In contrast, the I&D group in our study demonstrated a near-complete resolution rate of 97.1%, similar to findings reported previously and other authors, who have emphasized the advantage of I&D in breaking all loculi, thereby minimizing recurrence (2, 13).

Secondary outcomes highlighted the practical benefits of USGNA (6, 14). Patients in the USGNA group experienced significantly lower pain scores at 24 hours post-procedure compared to the I&D group (15, 16). Additionally, breastfeeding was resumed earlier (p < 0.001), and cosmetic satisfaction was higher (p < 0.001). These findings reinforce previous reports suggesting that USGNA, being minimally invasive, allows early maternal-infant bonding and better postoperative comfort (1, 17, 18).

Despite its advantages, USGNA carries the limitation of potential incomplete drainage, sometimes necessitating repeat aspirations (19). In our study, USGNA patients required a second aspiration, which is slightly lower than earlier studies reporting repeat aspiration rates up to 10–15%. This difference could be due to careful selection of patients with unilocular abscesses and real-time ultrasound guidance during aspiration (20). The choice of management should therefore be individualized. I&D remains the gold standard for large, multiloculated abscesses or cases at high risk of recurrence. Conversely, USGNA is an effective outpatient alternative for small to moderate, unilocular abscesses, offering the benefits of reduced pain, better cosmesis, and earlier breastfeeding resumption.

Conclusion

Our study confirms that both interventions are safe and effective in the management of lactational breast abscess. However, USGNA demonstrates clear advantages in patient comfort and postoperative quality of life without compromising clinical efficacy. Future multicentre studies with larger sample sizes could further validate these findings and help develop standardized treatment guidelines for lactational breast abscesses.

Declarations**Data Availability statement**

All data generated or analysed during the study are included in the manuscript.

Ethics approval and consent to participate

Approved by the department concerned. (IRBEC-SGRH/233-24)

Consent for publication

Approved

Funding

Not applicable

Conflict of interest

The authors declared the absence of a conflict of interest.

Author Contribution**NF (PGR), IA (HOD), SA (SR)**

Designed the study, collected the data, analyzed the results, and wrote the major part of the manuscript.

Contributed to the study design and supervised the research work.

Contributed to data collection and literature review.

AA (PGR), AA (PGR)

Assisted in data collection.

Also contributed to data collection.

All authors reviewed the results and approved the final version of the manuscript. They are also accountable for the integrity of the study.

References

- Totadri VM, Vetri R, Sainath S. A comparative study of drainage of breast abscesses by conventional incision and drainage vs ultrasound-guided needle aspiration/re-aspiration in a tertiary health care centre. *Eur J Breast Health.* 2024;20(3):194-8. <https://doi.org/10.4274/ejbh.galenos.2024.2024-3-2>
- Bhatti AM, Memon AI, Naz T, Latif S, Usman S, Gul A. Incision and drainage versus ultrasound guided needle aspiration in the management of lactational breast abscess. *Int J Endorsing Health Sci Res.* 2021;9(2):190-4. <https://doi.org/10.29052/IJEHSR.v9.i2.2021.190-194>
- Oliveira FS, Vieira F, Cecilio JO, Guimarães JV, Campbell SH. The effectiveness on health education to prevent nipple trauma from breastfeeding: a systematic review. *Rev Bras Saude Mater Infant.* 2020;20(2):333-45. <https://doi.org/10.1590/1806-9304202000200002>
- Donsu JD, Pont AV, Tandilimbong H, Rahman A. Breastfeeding techniques in breast milk dams of primipara mothers at gynecology room. *Pediatr Neonatal Med.* 2021;1(1):1-5. <https://doi.org/10.36266/RJSH/111>
- Pesce CE, Yao K. Abscess/infections/periareolar mastitis. *Ann Breast Surg.* 2021;5:25. <https://doi.org/10.21037/abs-21-49>
- Egbe TO, Njamen TN, Essome H, Tendongfor N. The estimated incidence of lactational breast abscess and description of its management by percutaneous aspiration at the Douala General Hospital, Cameroon. *Int Breastfeed J.* 2020;15:26. <https://doi.org/10.1186/s13006-020-00271-2>

- Luo J, Long T, Cai Y, Teng Y, Fan Z, Liang Z, et al. Abscess drainage with or without antibiotics in lactational breast abscess: study protocol for a randomized controlled trial. *Infect Drug Resist.* 2020;13:183-90. <https://doi.org/10.2147/IDR.S221037>
- Khan SM, Khan RAA, Qadir H, Ali S, Kausar S. Comparison of ultrasound guided needle aspiration (ASP) and incision and drainage (I&D) in lactating breast abscess. *Ann Punjab Med Coll.* 2022;16(3):180-3. <https://doi.org/10.29054/APMC/2022.1419>
- Ghunaim H. Percutaneous ultrasound-guided needle aspiration for management of breast abscesses: a review. *J Med Radiat Sci.* 2023;70(3):327-37. <https://doi.org/10.1002/jmrs.682>
- Praborini A, Mohan SW, Febriyanti D, Wulandari RA. Maintaining breastfeeding in mothers and infants following incision and drainage surgery for breast abscess: a case series. *Clin Lact.* 2025;16(3-4):232. <https://doi.org/10.1891/CL-2025-0003>
- Menegas S, Moayed S, Torres M. Abscess management: an evidence-based review for emergency medicine clinicians. *J Emerg Med.* 2021;60(3):310-20. <https://doi.org/10.1016/j.jemermed.2020.10.043>
- Lannon M, Trivedi A, Martyniuk A, Farrokhlyar F, Sharma S. Surgical aspiration versus excision for intraparenchymal abscess: a systematic review and meta-analysis. *Br J Neurosurg.* 2022;36(6):743-9. <https://doi.org/10.1080/02688697.2022.2118231>
- Surana K, Sagrude D, Lanjewar S. Primary closure with suction drain of acute breast abscess after incision, drainage, and curettage. *Indian J Surg.* 2020;82(2):129-33. <https://doi.org/10.1007/s12262-019-01899-z>
- Liu J, Sun C. Clinical application of minimally invasive therapy of lactational breast abscess. *Indian J Surg.* 2021;83(Suppl 2):427-30. <https://doi.org/10.1007/s12262-020-02290-z>
- Arif A, Aleem S, Naseem S, Aleem A, Khan A, Aleem N. Comparison of pain, cosmetic outcomes and early restoration of breast feeding in multiple percutaneous needle aspiration vs incision and drainage for small breast abscess management. *Pak J Health Sci.* 2025;6(5):257-62. <https://doi.org/10.54393/pjhs.v6i5.1725>
- Ali H, Aziz M, Iftikhar M, Munawar S, Qurban S. Comparing the efficacy of incision and drainage (I&D) vs ultrasound-guided needle aspiration (UGNA) methods to manage puerperal breast abscess. *Pak J Health Sci.* 2024;5(7):220-8. <https://doi.org/10.54393/pjhs.v5i07.1902>
- Pote MP, Gavit SM, Kurkure SA. To study the spectrum of breast diseases in reproductive age women in rural area: a study conducted at tertiary care center. *Int J Surg Sci.* 2020;4(3):348-52. <https://doi.org/10.33545/surgery.2020.v4.i3f.519>
- Bardales RH. Personal experience performing ultrasound-guided fine-needle aspiration of superficial masses. In: Bardales RH, editor. *The interventional cytopathologist: ultrasound guided fine-needle aspiration of superficial masses with ultrasound correlation.* 2nd ed. Cham: Springer; 2024. p. 371-93. https://doi.org/10.1007/978-3-031-73702-2_9
- Varman S. *Advanced irrigation and drainage techniques.* Educoback Press; 2025. DOI not available.
- Evans GY, Amarouche M, Minhas PS, Singh N. Ultrasound guided brain abscess aspiration. *Br J Neurosurg.* 2024;38(3):789-93. <https://doi.org/10.1080/02688697.2021.1961683>



Open Access This article is licensed under a Creative Commons Attribution NonCommercial 4.0 International License, <http://creativecommons.org/licenses/by-nc/4.0/>. © The Author(s) 2025