

Frequency of Molar-Incisor Hypomineralization in Children Visiting Department of Operative Dentistry & Endodontics at Hamdard University Dental Hospital Karachi

Hussain Bahadur Ali Lalani*, Syed Abrar Ali, Rida Rafique, Dua Shahid Ali, Hafiz Najm Us Saqib Siddiqui

Department of Operative Dentistry & Endodontics, Hamdard University Hospital Karachi, Pakistan

*Corresponding author's email address: hussain_lalani111@hotmail.com

(Received, 24th November 2024, Accepted 8th January 2025, Published 31st January 2025)

Abstract: Molar-incisor hypomineralization (MIH) is a prevalent developmental dental condition affecting the first permanent molars and incisors, leading to enamel defects, hypersensitivity, and increased risk of dental caries. Early detection is essential for timely management and prevention of complications. **Objective:** To determine the frequency of molar-incisor hypomineralization (MIH) in children visiting the Department of Operative Dentistry & Endodontics at Hamdard University Dental Hospital Karachi with complain of pain & sensitivity. **Methodology:** This cross-sectional study was conducted over six months and included 180 children presenting with complaints of pain, sensitivity, discoloration, or caries in one or more first permanent molars with or without involvement of incisors. Participants were selected using consecutive sampling. The diagnosis of MIH was based on criteria set by the European Academy of Paediatric Dentistry (EAPD). It included clinical examination for demarcated opacities, post-eruptive enamel breakdown, atypical restorations, and extractions of first permanent molars. Informed consent and assent were obtained from participants and their guardians. Data analysis was performed using SPSS Version 23, with quantitative data summarized as means and standard deviation and qualitative data as frequencies and percentages. Chi-square and Fisher's exact tests were used for associations, with significance set at $p \leq 0.05$. **Results:** The mean age of participants was 11.66 ± 2.73 years. The prevalence of MIH was 3.9%. Demarcated opacities were observed in 2.8% of participants, post-eruptive enamel breakdown in 2.2%, atypical restorations in 1.7%, and extractions of first permanent molars in 1.7%. MIH was more common in females (71.4%) than males (28.6%), and 85.7% of cases occurred in the 8–12-year age group. However, no significant associations were found between MIH and age or gender. **Conclusion:** The study highlights a low prevalence of MIH in the local population, with most cases occurring in younger children. Early diagnosis and intervention are crucial to managing this condition effectively and preventing long-term complications.

Keywords: Molar-incisor hypomineralization, demarcated opacities, post-eruptive enamel breakdown, atypical restorations, pediatric dentistry

[How to Cite: Lalani HBA, Ali SA, Rafique R, Ali DS, Siddiqui NUS. Frequency of molar-incisor hypomineralization in children visiting the Department of operative dentistry & endodontics at Hamdard university dental hospital Karachi. *Biol. Clin. Sci. Res. J.*, 2025; 6(1): 90-93. doi: <https://doi.org/10.54112/bcsrj.v6i1.1524>

Introduction

The word molar-incisor hypomineralisation (MIH) was introduced by Weerheijm et al. in 2001 to characterize the clinical manifestation of enamel hypomineralization for systemic origin, impacting one or more 1st permanent molars often in conjunction with affected incisors. Several terms, including non-fluoride enamel opacities, internal enamel hypoplasia, non-endemic mottling of enamel, idiopathic enamel opacities, and cheese molars refer to the condition. Estimates indicate that molar-incisor hypomineralisation (MIH) impacts approximately one in six children globally (1, 2).

During clinical examination, the teeth impacted by molar incisor hypomineralization exhibit a soft, delicate, and porous texture, resembling discolored chalk or aged Dutch cheese. The affected enamel exhibits white, whitish-yellow, or yellowish-brown colors and typically presents a distinct boundary separating the affected areas from the healthy enamel. Compromised teeth' delicate, porous enamel readily disintegrates under the pressure of chewing forces (3). The occurrence of MIH differs based on the country of origin. Reports documenting MIH across various countries globally indicate that prevalence rates range from 2.8% to 40.2%.^{1, (4)} The occurrence of MIH within the Chinese population was identified to be as low as 2.5%. (5). Studies in Brazil, Germany, Iraq, and Spain reported prevalence rates ranging from 10.1% to 21.8%. (6, 7). In contrast, countries such as India and Iran showed rates of MIH at 6.31% and 12.7%, respectively. A recent study in southern Punjab, Pakistan, identified a prevalence of MIH at 3.33% in that region (7).

Numerous pre- and perinatal conditions have been linked to the cause of MIH (7-10). Several medical factors, including prenatal, perinatal, and postnatal conditions, low birth weight, use of antibiotics, and exposure to toxins during breastfeeding, may contribute to MIH. However, the precise etiology of MIH remains unproven (6-10), and treating hypomineralized teeth presents a challenge in clinical settings. The challenges arise from the porosity of the hypomineralized enamel, the propensity for the clinical crown to deteriorate under standard occlusal function, and the persistent inflammation of pulpal tissues, all of which complicate the effective administration of anesthesia for these teeth. The lower mineral quality of these teeth can complicate the retention of restoration, and in severe instances, extraction of the teeth that are impacted may be necessary (11). Considering all the aforementioned facts, MIH presents a significant challenge for restorative dentists due to its considerable effect on oral health. This study aimed to assess the frequency of molar-incisor hypomineralization in children attending the Department of Operative Dentistry & Endodontics at Hamdard University Dental Hospital Karachi. This research aims to raise awareness within the local community and the dental profession about the rising incidence of molar-incisor hypomineralization, facilitating early detection and diagnosis, which is crucial for preventing potential complications. This study will enable us to assess the prevalence of this condition within the local population attending our teaching institute.



Methodology

After obtaining ethical approval, the study was conducted as a cross-sectional investigation at the Department of Operative Dentistry & Endodontics, Hamdard University Dental Hospital Karachi. The study spanned six months, from 30-04-2023 to 30-10-2023. It included children aged 8 to 16 years presenting with complaints of pain, sensitivity, discoloration, or caries involving one or more first permanent molars with or without the involvement of incisors. A total of 180 participants were included using a consecutive sampling technique. The sample size was calculated using OpenEpi software with an assumed frequency of MIH at 4.4%¹², a margin of error of 3%, and a 95% confidence interval.

Clinical examinations were performed by a trained examiner on all children in a dental chair under appropriate lighting conditions, using a mirror, dental explorer, and dental light. Diagnostic criteria were based on the European Academy of Paediatric Dentistry (EAPD) recommendations. Before the examinations, teeth were cleaned using prophylactic paste and a rotary brush, and fissures were further cleaned with a dental explorer to ensure accurate assessment. Teeth were kept wet during the examination to avoid misdiagnosis due to drying effects. The examiner assessed the first permanent molars and incisors for demarcated opacities, post-eruptive breakdown, atypical restorations, and extractions of the first permanent molars. MIH was diagnosed if one or more first permanent molars, with or without associated incisors, met the criteria. A second expert re-examined diagnosed cases to minimize bias.

Informed consent was obtained from parents, and assent was secured from children before their participation. Exclusion criteria included refusal to participate, generalized opacities affecting all teeth, fluorosis involving teeth beyond the target molars and incisors, opacities unrelated to MIH (such as those due to trauma or infection), and cases involving generalized developmental conditions like amelogenesis imperfecta.

Data collected included demographic information and clinical features related to MIH. Quantitative variables such as age were summarized as means and standard deviations. In contrast, qualitative variables were presented as frequencies and percentages, including the presence of demarcated opacities, post-eruptive enamel breakdown, atypical restorations, and extracted first molars. The normality of the data was tested using the Shapiro-Wilk test. Stratification of data by age and gender was performed, and chi-square or Fisher's exact tests were used to

evaluate associations, with a p-value of ≤ 0.05 considered statistically significant. Data analysis was performed using SPSS Version 23.

Results

The study included 180 participants aged between 8 and 16 years, with a mean age of 11.66 ± 2.73 years. The age distribution showed that 58.9% of the participants were between 8 and 12 years, while 41.1% were aged 13 to 16. (Figure 1) Regarding gender, 102 participants (56.7%) were male, and 78 (43.3%) were female. (Table 1) The clinical features observed among the participants included demarcated opacities in 5 cases (2.8%), post-eruptive enamel breakdown in 4 cases (2.2%), atypical restorations in 3 cases (1.7%), and extracted first molars in 3 cases (1.7%). (Table 2) The frequency of molar-incisor hypomineralization (MIH) was found in 7 participants (3.9%), while the remaining 173 participants (96.1%) did not exhibit MIH. (Table 3)

When exploring the association of MIH with demographics, among the MIH-positive cases, 2 participants (28.6%) were male, and 5 participants (71.4%) were female ($p = 0.12$). Age-wise, 6 participants (85.7%) with MIH were in the 8 to 12 years age group, while 1 participant (14.3%) was in the 13 to 16 years age group ($p = 0.14$). (Table 4)

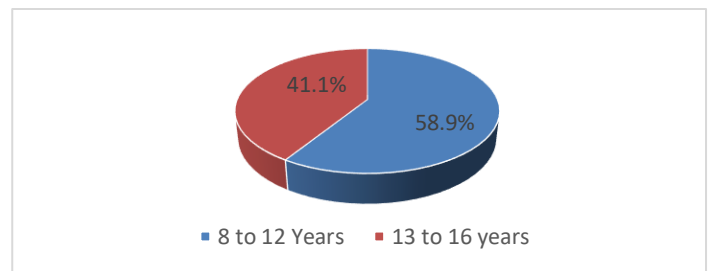


Figure 1 Age distribution

Table 1 Gender distribution

Gender	Frequency	Percent
Male	102	56.7
Female	78	43.3
Total	180	100.0

Table 2 Clinical features of patients

Clinical Features of Patients		Frequency	Percentage
Demarcated opacities	Seen	5	2.8%
	Not seen	175	97.2%
Post-eruptive enamel breakdown	Seen	4	2.2%
	Not seen	176	97.8%
Atypical restoration	Seen	3	1.7%
	Not seen	177	98.3%
Extracted first molar	Seen	3	1.7%
	Not seen	177	98.3%

Table 3 Frequency of molar incisor hypomineralization

Molar incisor hypomineralization	Frequency	Percent
Yes	7	3.9
No	173	96.1
Total	180	100.0

Table 4 Association of molar incisor hypomineralization with demographics

Demographics		Molar incisor hypomineralization				P value
		Yes		No		
		Frequency	Percentage	Frequency	Percentage	
Gender	Male	2	28.6%	100	57.8%	0.12
	Female	5	71.4%	73	42.2%	
Age distribution (Years)	8 to 12	6	85.7%	100	57.8%	0.14

Discussion

The frequency of molar-incisor hypomineralization (MIH) in this study was found to be 3.9%, which aligns with findings from several regions that reported varying prevalence rates of MIH globally. For instance, Abdalla et al. noted a prevalence of 20.1% in Sudanese children, with demarcated opacities being the most common defect (69.9%) in affected teeth. While our study reported a lower prevalence, similar characteristics of hypomineralized enamel, such as demarcated opacities, were observed at a much lower rate of 2.8% (14). This discrepancy could stem from differences in the studied populations, methodologies, or diagnostic criteria. Abdalla et al. also highlighted a high occurrence of maxillary incisors being affected, which was not explicitly explored in our dataset but could provide valuable insights into the anatomical distribution of MIH defects (14).

The age distribution in our study revealed that 85.7% of MIH cases occurred in children aged 8 to 12 years, consistent with reports emphasizing the critical age range for detecting MIH due to the eruption timing of permanent first molars and incisors. A literature review by Pérez Navarro et al. also highlighted that children in this age group are more likely to show the clinical signs of MIH since these teeth are newly erupted and more vulnerable to structural breakdown (15). Similarly, Mohamed et al. observed that MIH is prevalent among younger children with special healthcare needs, further underscoring the significance of early diagnosis and intervention (16). Our findings align with this pattern, indicating the importance of targeted screening in younger populations.

Gender analysis in this study showed a slightly higher prevalence of MIH in females (71.4%) compared to males (28.6%), although the association was not statistically significant. This trend mirrors findings in some regional studies, such as Ortega-Luengo et al., who observed a higher prevalence of MIH in girls (60.71%) in Madrid, Spain (17). The reasons for this discrepancy could be multifactorial, involving potential biological differences in enamel development or sociocultural factors influencing health-seeking behavior. However, other studies, such as Afshari et al.'s systematic review in Iran, reported no significant gender-based prevalence differences, suggesting that the role of gender in MIH prevalence might vary by region (18).

In terms of clinical features, demarcated opacities, post-eruptive enamel breakdown, and atypical restorations are hallmark characteristics of MIH. Our study reported low frequencies for these features: demarcated opacities (2.8%), post-eruptive enamel breakdown (2.2%), and atypical restorations (1.7%). These findings contrast with several global studies where these features are more prominent in MIH cases. For instance, in Sudan, Abdalla et al. found demarcated opacities in most MIH cases, indicating that this feature remains a primary diagnostic marker worldwide (14). Similarly, Nisii et al. observed a high frequency of post-eruptive breakdown and demarcated opacities in Italian children, emphasizing the importance of these clinical features in identifying MIH (19). The lower frequency in our sample could be attributed to the overall low prevalence of MIH in the studied population.

The extraction of the first permanent molars due to MIH was observed in 1.7% of our participants. This finding aligns with other studies emphasizing the severe consequences of untreated MIH, including tooth loss and the need for atypical restorations (15-17). Studies by Mohamed et al. and Ortega-Luengo et al. reported similar observations, linking the severity of MIH with increased extraction and dental intervention (16, 17). These findings highlight the clinical burden of MIH, especially in severe cases, and the importance of preventive strategies and early management.

Comparing the prevalence of MIH globally, Pérez Navarro et al. reported a global prevalence of 9.4%, with regional variations ranging from 4.9% in Africa to 17.7% in America (15). Our findings fall below these estimates, particularly the African regional prevalence, which might reflect the smaller sample size and local differences in risk factors such as environmental or genetic predispositions. Furthermore, Mohamed et al.

and Afshari et al. discussed the role of prenatal, perinatal, and postnatal factors in MIH development, including childhood illnesses, antibiotic use, and nutritional deficiencies, which could contribute to regional disparities in prevalence (16-18). These factors were not directly explored in our study but represent an area for future investigation.

Conclusion

In conclusion, the study highlights the frequency of molar-incisor hypomineralization (3.9%) in the examined population, with clinical manifestations such as demarcated opacities and post-eruptive enamel breakdown occurring infrequently. MIH was more prevalent in younger children aged 8–12 years and showed a slight, non-significant gender disparity towards females. These findings underscore the importance of early detection and targeted interventions to manage MIH effectively and prevent its long-term complications.

Declarations

Data Availability statement

All data generated or analyzed during the study are included in the manuscript.

Ethics approval and consent to participate

Approved by the department concerned. (ERB-2022-14)

Consent for publication

Approved

Funding

Not applicable

Conflict of interest

The authors declared the absence of a conflict of interest.

Author Contribution

HBAL (Post Graduate Resident)

Manuscript drafting, Study Design, Review of Literature, Data entry, Data analysis, drafting article, and Development of Research Methodology Design

SAA (Professor)

Conception of Study.

RR, DSA, HNUSS (General Dentist)

Collaborative effort, literature search and review

All authors reviewed the results and approved the final version of the manuscript. They are also accountable for the integrity of the study.

References

1. Almuallem Z, Busuttil-Naudi A. Molar incisor hypomineralisation (MIH)—an Overview. *Br Dent J.* 2018; 225(7):601-9.
2. Hubbard MJ. Molar hypomineralization: What is the US experience? *The J American Dent Assoc.* 2018; 149(5):329-30.
3. Allazzam SM, Alaki SM, El Meligy OA. Molar incisor hypomineralization, prevalence, and etiology. *Int J Dent.* 2014; 2014.
4. Ghanim A, Silva MJ, Elfrink ME, Lygidakis NA, Mariño RJ, Weerheijm KL, et al. Molar incisor hypomineralisation (MIH) training manual for clinical field surveys and practice. *Eur Arch Paediatr Dent.* 2017; 18(4):225-42.
5. da Silva Figueiredo Sé MJ, Ribeiro AP, dos Santos-Pinto LA, de Cassia Loiola Cordeiro R, Cabral RN, et al. Are hypomineralized primary molars and canines associated with molar-incisor hypomineralization? *Pediatr Dent.* 2017; 39(7):445-9.

6. Tourino LF, Corrêa-Faria P, Ferreira RC, Bendo CB, Zarzar PM, Vale MP. Association between molar incisor hypomineralization in schoolchildren and both prenatal and postnatal factors: a population-based study. *PloS One*. 2016; 11(6):e0156332.
7. Zafar R, Urooj A, Masood S. Frequency of Molar Incisor Hypomineralization and Associated Risk Factors—A Study from Southern Punjab, Pakistan. *Biomedica*. 2020; 36(3):291.
8. Mittal NP, Goyal A, Gauba K, Kapur A. Molar incisor hypomineralisation: prevalence and clinical presentation in school children of the northern region of India. *Eur Arch Paediatr Dent*. 2014; 15(1):11-8.
9. Ahmadi R, Ramazani N, Nourinasab R. Molar incisor hypomineralization: a study of prevalence and etiology in a group of Iranian children. *Iran J Pediatr*. 2012; 22(2):245.
10. Davenport M, Welles AD, Angelopoulou MV, Gonzalez C, Okunseri C, Barbeau L, Bansal NK, Vergotine RJ, Hodgson BD. Prevalence of molar-incisor hypomineralization in Milwaukee, Wisconsin, USA: a pilot study. *Clin Cosmet Investig Dent*. 2019; 11:109.
11. Hoyte T, Kowlessar A, Ali A, Bearn D. Cross-Sectional survey to ascertain the prevalence of Molar Incisor Hypo-mineralization in the Trinidad and Tobago population. *Am J Biomed Res*. 2020; 7(3):204-7.
12. Jurlina D, Uzarevic Z, Ivanisevic Z, Matijevec N, Matijevec M. Prevalence of Molar–Incisor Hypomineralization and Caries in Eight-Year-Old Children in Croatia. *Int J Environ Res Public Health*. 2020; 17(17):6358.
13. Weerheijm KL, Duggal M, Mejare I, Papagiannoulis L, Koch G, Martens LC, Et al. Judgement criteria for Molar Incisor Hypomineralisation (MIH) in epidemiologic studies: A summary of the European meeting on MIH held in Athens, 2003. *Eur J Paediatr Dent*. 2003; 4:110-4.
14. Abdalla HE, Abuaffan AH, Kemoli AM. Molar incisor hypomineralization, prevalence, pattern and distribution in Sudanese children. *BMC Oral Health*. 2021;21(9): 1-8
15. Pérez Navarro N, Buldur B. Worldwide prevalence of molar-incisor hypomineralization: A literature review. *Contemp Pediatr Dent*. 2024; 5(1):15-33.
16. Mohamed RN, Basha S, Al-Thomali Y, et al. Frequency of molar incisor hypomineralization and associated factors among children with special health care needs. *Ann Saudi Med*. 2021; 41(4):238-245.
17. Ortega-Luengo S, Feijóo-García G, Miegimolle-Herrero M, et al. Prevalence and clinical presentation of molar incisor hypomineralisation among a population of children in the community of Madrid. *BMC Oral Health*. 2024; 24(229).
18. Afshari E, Dehghan F, Vakili MA, Abbasi M. Prevalence of molar-incisor hypomineralization in Iranian children – A systematic review and narrative synthesis. *BDJ Open*. 2022; 8(15).
19. Nisii F, Mazur M, De Nuccio C, et al. Prevalence of molar incisor hypomineralization among school children in Rome, Italy. *Sci Rep*. 2022;12 (1):7343.



Open Access This article is licensed under a Creative Commons Attribution 4.0 International License, <http://creativecommons.org/licenses/by/4.0/>. © The Author(s) 2025