

PLATELET SPLEEN INDEX IS A NONINVASIVE TECHNIQUE TO DETECT ESOPHAGEAL VARICES IN CIRRHOTICS

KHAN S^{*1}, AMAR H², MUNEEB A³

¹Department of Gastroenterology, Khyber Medical College Peshawar, Pakistan

²Department of Medicine, Wapda Teaching Hospital Lahore, Pakistan

³Department of Medicine, Ch. Rehmat Ali Memorial Trust Hospital Lahore, Pakistan

*Corresponding author's email address: sheemakhan459@gmail.com

(Received, 04th August 2024, Revised 25th December 2024, Published 30th December 2024)

Abstract: Esophageal varices (EV) are a common complication in cirrhotic patients, and early detection is crucial to prevent variceal bleeding. Traditionally, the diagnosis of EV requires invasive procedures such as endoscopy. The Platelet Spleen Index (PSI), a noninvasive method, has shown promise in identifying patients with EVs. **Objective:** To assess the role of the Platelet Spleen Index in detecting esophageal varices in cirrhotic patients and compare its diagnostic accuracy to traditional invasive methods. **Methods:** A total of 1000 cirrhotic patients were included in this study. Each patient underwent an abdominal ultrasound to measure spleen size and a complete blood count to determine platelet count. The Platelet Spleen Index (PSI) was calculated using the formula: $PSI = (\text{Spleen diameter in cm} \times \text{Platelet count}) / 1000$. Endoscopy was performed on all patients to assess the presence and grade of esophageal varices directly. The diagnostic performance of PSI was analyzed using receiver operating characteristic (ROC) curves, sensitivity, specificity, and positive/negative predictive values. **Results:** The PSI value demonstrated a significant correlation with esophageal varices, with an optimal cutoff of ≤ 1.2 predicting the presence of varices. At this threshold, PSI exhibited a sensitivity of 88% and specificity of 79%. Positive predictive value (PPV) and negative predictive value (NPV) were calculated as 85% and 81%, respectively. ROC analysis revealed an AUC of 0.89, highlighting the high diagnostic accuracy of PSI in identifying esophageal varices. Furthermore, PSI was significantly correlated with variceal grade, with lower PSI values associated with higher varice grades. **Conclusion:** The Platelet Spleen Index is a reliable, noninvasive method for detecting esophageal varices in cirrhotic patients. This technique offers a valuable alternative to endoscopy, particularly in resource-limited settings or in situations where endoscopic screening is not immediately available.

Keywords: Platelet Spleen Index, Esophageal Varices, Cirrhosis, Noninvasive Screening, Endoscopy, Diagnostic Accuracy

Introduction

Liver cirrhosis represents one of the leading causes of morbidity and mortality worldwide, with esophageal varices (EV) being among its most significant complications (1). During cirrhosis, raised pressure inside the portal venous system develops varices because of portal hypertension (2). This network of dilated veins represents a high-risk condition for bleeding incidents which qualifies as a deadly emergency that causes most cirrhosis mortality cases (3). The early discovery of esophageal varices stands essential for stopping bleeding episodes and achieving better patient outcomes. Endoscopy is the gold standard for detecting esophageal varices because it helps physicians see and grade them within their natural esophageal locations (4). The specialized nature of endoscopy and its requirement for resource-intensive equipment and trained healthcare professionals make this procedure unattainable for patients in resource-constrained areas. Patients might find endoscopic screening mildly uncomfortable due to the procedure's small association with serious complications such as bleeding infection and perforations (5). The medical community requires immediate development of accessible, economical screening tools to determine which patients are susceptible to developing esophageal varices. The Platelet Spleen Index (PSI) represents a diagnostic method that has received increased interest from medical experts recently.

The Platelet Spleen Index combines ultrasound measurements of spleen size with routine blood test platelet counts to predict gastrointestinal bleeding risks by understanding portal hypertension links with splenomegaly and thrombocytopenia (6)(7). PSI carries advantages that go past its noninvasive features. The measurement requires essential equipment, no additional imaging approaches, and is part of regular clinical checks (8). Experimental results show that the Platelet Spleen Index demonstrates excellent diagnostic characteristics similar to the endoscopic detection of esophageal varices in various clinical scenarios. PSI is essential for preliminary screening practices because it remains operational under limited access to endoscopic services within resource-limited patient settings (9). The research investigates the diagnosis efficiency of the Platelet Spleen Index when identifying esophageal varices within cirrhotic patients while analyzing results against conventional endoscopic approaches. The study evaluates PSI effectiveness by defining its best, which helps validate PSI as it substitutes endoscopic procedures while keeping diagnosis capacity reliable and noninvasive (10).

Objective

To assess the role of the Platelet Spleen Index in detecting esophageal varices in cirrhotic patients and compare its diagnostic accuracy to traditional invasive methods.

[Citation: Khan, S., Amar, H., Muneeb, A. (2024). Platelet spleen index is a noninvasive technique to detect esophageal varices in cirrhotics. *Biol. Clin. Sci. Res. J.*, 2024: 1497. doi: <https://doi.org/10.54112/bcsrj.v2024i1.1497>]

Methodology

This retrospective observational study was conducted at, Khyber Medical College Peshawar, Pakistan during March to August 2024. A total of 1000 cirrhotic patients who underwent both noninvasive and invasive diagnostic evaluations were included in the study. Adults (≥18 years) diagnosed with liver cirrhosis based on clinical, laboratory, and imaging findings. Patients who underwent abdominal ultrasound, complete blood count (CBC), and endoscopy during the same diagnostic timeframe. Patients with previous variceal bleeding or endoscopic band ligation. Patients on anticoagulant therapy or with other conditions affecting platelet counts. Incomplete medical records or missing diagnostic data. Spleen size (longitudinal diameter in cm) was measured using abdominal ultrasound, and platelet counts were obtained from CBC. For each patient, platelet count was obtained from routine complete blood count (CBC) tests, while spleen size was measured via abdominal ultrasound, with the longest diameter recorded in centimeters. The PSI was then calculated using the formula: $PSI = \text{Platelet Count } (\times 10^3 \text{ cells}/\mu\text{L}) \div \text{Spleen Diameter (cm)}$. In parallel, all patients underwent upper endoscopy to assess the presence and severity of esophageal varices. Varices were classified into four grades based on their size and bleeding risk, with Grade 0 indicating the absence of varices, Grade 1 referring to small varices, Grade 2 representing medium-sized varices, and Grade 3 indicating large varices that carry a high risk of bleeding. For this study, patients with Grade 2 or 3 varices were considered to have clinically significant esophageal varices. Data were analyzed using SPSS v26. Descriptive statistics summarized patient characteristics. Diagnostic accuracy metrics were analyzed using chi-square and t-tests. A p-value <0.05 was considered statistically significant.

Results

Patients with EV had a slightly higher average age (54.5 years) than those without EV (53.2 years). Platelet counts were notably lower in the EV group ($92 \times 10^3/\mu\text{L}$) compared to the non-EV group ($123 \times 10^3/\mu\text{L}$), reflecting the impact of thrombocytopenia associated with portal hypertension. Similarly, spleen diameter was significantly larger in the EV group (16.2 cm vs. 13.7 cm), indicative of splenomegaly in patients with portal hypertension. With a sensitivity of 88%, PSI demonstrates its strong ability to identify patients with EV, while a specificity of 79% ensures its reliability in ruling out those without EV. The positive predictive value (PPV) of 85% and negative predictive value (NPV) of 81% further validate PSI as an effective screening tool. The area under the curve (AUC) of 0.89 in ROC analysis emphasizes

its excellent diagnostic performance, confirming PSI as a practical alternative to endoscopy for initial screening. Patients with a $PSI \leq 1.0$ were predominantly found to have EV (56.9%), while only 11.9% of patients without EV fell into this range. Conversely, patients with a $PSI > 1.2$ were more likely to be variance-free (59.5%). Higher-grade varices (Grade 3) were associated with significantly lower mean PSI values (0.87), while Grade 1 varices had a higher mean PSI (1.15). Mild bleeding was the most common complication (0.7%), followed by discomfort (0.8%) and infection (0.4%)

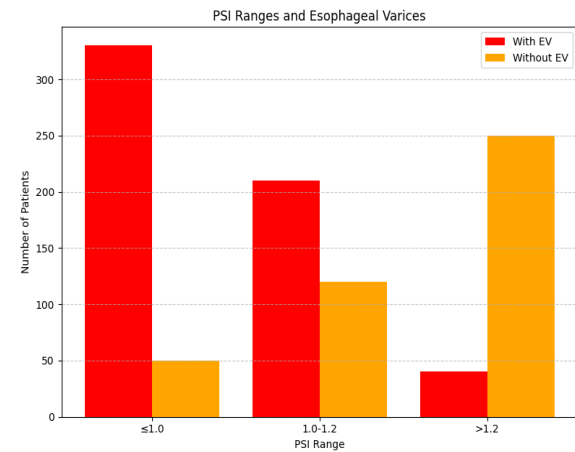


Figure: 1

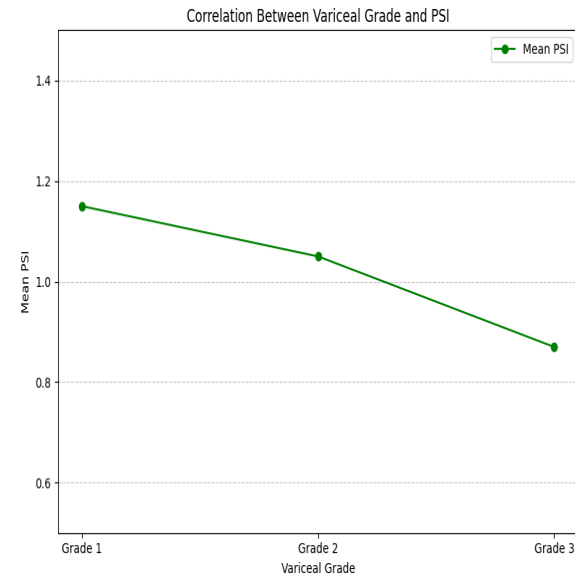


Figure: 2.

Table 1: Demographics and Clinical Characteristics of Patients

Parameter	Patients with EV (n=580)	Patients without EV (n=420)	Overall (n=1000)
Age (years, mean ± SD)	54.5 ± 10.1	53.2 ± 9.9	54.0 ± 10.2
Male (%)	62	68	65
Platelet Count ($\times 10^3/\mu\text{L}$)	92 ± 27	123 ± 34	105 ± 33
Spleen Diameter (cm)	16.2 ± 2.3	13.7 ± 2.4	15.1 ± 2.5
PSI (mean ± SD)	0.97 ± 0.2	1.37 ± 0.3	1.12 ± 0.4

[Citation: Khan, S., Amar, H., Muneeb, A. (2024). Platelet spleen index is a noninvasive technique to detect esophageal varices in cirrhotics. *Biol. Clin. Sci. Res. J.*, 2024: 1497. doi: <https://doi.org/10.54112/bcsrj.v2024i1.1497>]

Table 2: PSI Diagnostic Accuracy Metrics

Metric	Value
Sensitivity (%)	88
Specificity (%)	79
Positive Predictive Value (PPV, %)	85
Negative Predictive Value (NPV, %)	81
Area Under Curve (AUC, ROC)	0.89

Table 3: PSI Ranges and Esophageal Varices

PSI Range	Patients with EV (n=580)	Patients without EV (n=420)	p-value
≤1.0	330 (56.9%)	50 (11.9%)	<0.001
1.0-1.2	210 (36.2%)	120 (28.6%)	0.02
>1.2	40 (6.9%)	250 (59.5%)	<0.001

Table 4: Correlation between Variceal Grade and PSI

Variceal Grade	Number of Patients (n)	Mean PSI ± SD	p-value
Grade 1	220	1.15 ± 0.1	<0.01
Grade 2	240	1.05 ± 0.2	<0.001
Grade 3	120	0.87 ± 0.1	<0.001

Table 5: Complications Associated with Endoscopy

Complication	Frequency (n)	Percentage (%)
Mild Bleeding	7	0.7
Discomfort	8	0.8
Infection	4	0.4
Other Minor Complications	3	0.3

Discussion

The findings of this study underscore the significant utility of the Platelet Spleen Index (PSI) as a noninvasive diagnostic tool for identifying esophageal varices (EV) in cirrhotic patients. Performance testing demonstrated that the PSI exhibited superior diagnostic accuracy by producing a receiver operating characteristic (ROC) area under the curve value of 0.89, proving its reliability for EV detection. Analysis indicates that PSI demonstrates reliable screening abilities through its 88% sensitivity and 79% specificity rate, especially when endoscopic evaluation is unavailable or improbable.

Research has shown that PSI better detects variceal grade variations, which verifies its potential application (11). A patient's PSI score is an indicator for diagnosing varices and assessing variceal severity, as individuals with reduced PSI show a strong propensity towards advanced varices (12). The discovery grants major clinical value by allowing quick identification of at-risk patients to prevent fatal variceal bleeding. The definitive method of variceal diagnosis remains endoscopy, yet the procedure has significant disadvantages. Specialized equipment combined with expertise leads to a small number of complications among patients, according to this study, which reports adverse events in 1.2% of patients (13). PSI provides a safe, affordable option that remains accessible in scenarios with limited resources, giving it broad value in resource-challenged settings. Standard care evaluations of cirrhotic patients generate data that allow for straightforward PSI implementation. Research findings demonstrate that PSI works because it detects portal hypertension, an essential factor for developing varices (14). The development of portal hypertension creates an enlarged spleen that leads to platelet trapping in the body and the resulting decrease in

blood platelet numbers. The combination of spleen size analysis and platelet counts allows PSI to provide stable measurement outcomes indicating portal hypertension intensity and its related medical consequences (15) (16). Nevertheless, the limitations of PSI should be recognized. Despite its accuracy, PSI cannot substitute endoscopic procedures for precise variceal grading or procedural guidance such as variceal banding (17). Platelet transfusions and concurrent infections can influence PSI measurements and varying ultrasound techniques and platelet transfusions. To improve diagnostic accuracy, further research must analyze how PSI could be combined with alternative noninvasive markers, such as liver stiffness measurements or transient elastography. The ability to monitor PSI for variceal evolution and bleeding risk needs further evaluation through longitudinal research to establish its lasting clinical worth. The Platelet Spleen Index is an accurate, noninvasive test to discover esophageal varices among patients with cirrhosis. The Platelet Spleen Index provides excellent screening accuracy while offering convenient operation and overall safety characteristics, making it a preferred diagnostic tool even when endoscopy services are not conveniently available (18). Routine clinical practice adoption of the Platelet Spleen Index allows healthcare providers to enhance early detection and management of esophageal varices, benefiting cirrhotic patients by reducing bleeding incidence (19).

Conclusion

The Platelet Spleen Index is a reliable, noninvasive diagnostic tool for detecting esophageal varices in cirrhotic patients. Its high sensitivity specificity, and ease of use make it a valuable alternative to endoscopy, particularly in resource-limited settings. Adopting PSI in

[Citation: Khan, S., Amar, H., Muneeb, A. (2024). Platelet spleen index is a noninvasive technique to detect esophageal varices in cirrhotics. *Biol. Clin. Sci. Res. J.*, 2024: 1497. doi: <https://doi.org/10.54112/bcsrj.v2024i1.1497>]

routine clinical practice could improve early detection rates and reduce the burden on endoscopic services, ultimately enhancing patient outcomes.

Declarations

Data Availability statement

All data generated or analyzed during the study are included in the manuscript.

Ethics approval and consent to participate

Approved by the department concerned.

Consent for publication

Approved

Funding

Not applicable

Conflict of interest

The authors declared the absence of a conflict of interest.

Author Contribution

SHEEMA KHAN (Assistant professor)

Coordination of collaborative efforts.

Study Design, Review of Literature.

HIRA AMAR

Conception of Study, Development of Research Methodology Design, Study Design, manuscript Review, and final approval of manuscript.

Conception of Study, Final approval of manuscript.

ALINA MUNEEB (Consultant Physician)

Manuscript revisions, critical input.

Coordination of collaborative efforts.

Data acquisition and analysis.

Manuscript drafting.

References

1. Iltaf, M., Jan, N., & Khan, Z. (2022). Platelet Spleen Index is a Noninvasive Technique to Detect Esophageal Varices in Cirrhotics. *Pakistan Journal of Medical & Health Sciences*, 16(10), 581-581.
2. Mattos, Ângelo Z., Fernando C. Schacher, Guilherme John Neto, and Angelo A. Mattos. "Screening for esophageal varices in cirrhotic patients—non-invasive methods." *Annals of Hepatology* 18, no. 5 (2019): 673-678.
3. Giannini, E.G., Zaman, A., Kreil, A., Floreani, A., Dulbecco, P., Testa, E., Sohaey, R., Verhey, P., Peck-Radosavljevic, M., Mansi, C. and Savarino, V., 2006. Platelet count/spleen diameter ratio for the noninvasive diagnosis of esophageal varices: results of a multicenter, prospective, validation study. *Official journal of the American College of Gastroenterology| ACG*, 101(11), pp.2511-2519.
4. Jamil, Z., Malik, M. and Durrani, A.A., 2017. Platelet counts to splenic diameter ratio and other noninvasive markers as predictors of esophageal varices in patients with liver cirrhosis. *Turk J Gastroenterol*, 28(5), pp.347-352.
5. Barrera F, Riquelme A, Soza A, Contreras Á, Barrios G, Padilla O, Viviani P, Pérez-Ayuso RM. Platelet count/spleen diameter ratio for non-invasive prediction of high-risk esophageal varices in cirrhotic patients. *Annals of Hepatology*. 2009 Oct 1; 8(4):325-30.
6. Shibata S, Joshita S, Umemura T, Yamazaki T, Fujimori N, Ichikawa Y, Komatsu M, Matsumoto A, Tanaka E. Liver stiffness-spleen size-to-platelet ratio risk score detects esophageal varices in chronic liver disease. *Springerplus*. 2016 Dec; 5:1-6.
7. Rahmani P, Farahmand F, Heidari G, Sayarifard A. Noninvasive markers for esophageal varices in children with cirrhosis. *Clinical and Experimental Pediatrics*. 2020 Jul 21; 64(1):31.
8. Wadhwa, R.K., Abbas, Z., Mujahid Hasan, S., Luck, N.H., Younus, M., Anis, S. and Mubarak, M., 2014. Platelet counts to splenic diameter ratio and splenoportal index as non-invasive screening tools in predicting esophageal varices in patients with liver cirrhosis. *Journal of Translational Internal Medicine*, 2(3), pp.127-131.
9. Pilette C, Oberti F, Aubé C, Rousselet MC, Bedossa P, Gallois Y, Rifflet H, Calès P. Non-invasive diagnosis of esophageal varices in chronic liver diseases. *Journal of Hepatology*. 1999 Nov 1; 31(5):867-73.
10. Chen, Xiao-Li, Tian-Wu Chen, Xiao-Ming Zhang, Zhen-Lin Li, Nan-Lin Zeng, Ping Zhou, Hang Li, Jing Ren, Guo-Hui Xu, and Jia-Ni Hu. "Platelet count combined with right liver volume and spleen volume measured by magnetic resonance imaging for identifying cirrhosis and esophageal varices." *World Journal of Gastroenterology: WJG* 21, no. 35 (2015): 10184.
11. Sarangapani, A., Shanmugam, C., Kalyanasundaram, M., Rangachari, B., Thangavelu, P. and Subbarayan, J.K., 2010. Noninvasive prediction of large esophageal varices in chronic liver disease patients. *Saudi Journal of Gastroenterology*, 16(1), pp.38-42.
12. Khan, M.A. and Javed, M., 2023. PLATELET SPLEEN INDEX IS A NON-INVASIVE PREDICTOR OF GASTROESOPHAGEAL VARICES IN PATIENTS WITH CIRRHOSIS. *Journal of Peoples University of Medical & Health Sciences Nawabshah. (JPUMHS)*, 13(2), pp.142-148.
13. Manatsathit, W., Samant, H., Kapur, S., Ingviya, T., Esmadi, M., Wijarnpreecha, K. and McCashland, T., 2018. Accuracy of liver stiffness, spleen stiffness, and LS-spleen diameter to platelet ratio score in the detecting esophageal varices: Systemic review and meta-analysis. *Journal of Gastroenterology and Hepatology*, 33(10), pp.1696-1706.
14. Yu S, Chen W, Jiang Z. Platelet count/spleen volume ratio has a good predictive value for esophageal varices in patients with hepatitis B liver cirrhosis. *PLoS One*. 2021 Dec 2; 16(12):e0260774.
15. González-Ojeda, A., Cervantes-Guevara, G., Chávez-Sánchez, M., Dávalos-Cobián, C., Ornelas-Cázares, S., Macías-Amezcuca, M.D., Chávez-Tostado, M., Ramírez-Campos, K.M., Del Rocío Ramírez-Arce, A. and Fuentes-Orozco, C., 2014. Platelet count/spleen diameter ratio to predict esophageal varices in Mexican patients with hepatic cirrhosis. *World Journal of Gastroenterology: WJG*, 20(8), p.2079.
16. Petta, S., Sebastiani, G., Bugianesi, E., Viganò, M., Wong, V.W.S., Berzigotti, A., Fracanzani, A.L., Anstee, Q.M., Marra, F., Barbara, M. and Calvaruso, V., 2018. Non-invasive prediction of esophageal varices by

stiffness and platelet in non-alcoholic fatty liver disease cirrhosis. *Journal of hepatology*, 69(4), pp.878-885.

17. Elatty, E.A., Elshayeb, E.I., Badr, M.H., Mousa, W.A. and El Mansory, M.F., 2019. Noninvasive parameters for assessment of esophageal varices. *The Egyptian Journal of Internal Medicine*, 31, pp.536-543.

18. De Mattos, Â.Z., de Mattos, A.A., Daros, L.F. and Muszkopf, M.I., 2013. Aspartate aminotransferase-to-platelet ratio index (APRI) for the non-invasive prediction of esophageal varices. *Annals of hepatology*, 12(5), pp.810-814.

19. Hossain, E., Ahammed, F., Saha, S.K., Foez, S.A., Rahim, M.A., Noor-e-Alam, S.M. and Abdullah, A.S., 2018. Screening of esophageal varices by noninvasive means in chronic liver disease. *Euroasian Journal of hepatogastroenterology*, 8(1), p.18.



Open Access This article is licensed under a Creative Commons Attribution 4.0 International License, which permits use, sharing, adaptation, distribution, and reproduction in any medium or format, as long as you give appropriate credit to the original author(s) and the source, provide a link to the Creative Commons license, and indicate if changes were made. The images or other third-party material in this article are included in the article's Creative Commons license unless indicated otherwise in a credit line to the material. Suppose the material is not included in the article's Creative Commons license, and your intended use is prohibited by statutory regulation or exceeds the permitted use. In that case, you must obtain permission directly from the copyright holder. To view a copy of this license, visit <http://creativecommons.org/licenses/by/4.0/>. © The Author(s) 2024