

ANATOMICAL VARIATIONS IN ARTERIAL SUPPLY OF THUMB AND INDEX FINGER IN CADAVERIC HANDS



INAM T¹, TAFWEEZ R², BUKHARI ZH¹, KHALID W*³

¹Department of Anatomy, King Edward Medical University, Lahore-Pakistan

²Department of Anatomy, Azra Naheed Medical College Lahore-Pakistan

³Department of cardiac surgery Rehmatul lil Alameen Institute of cardiology Lahore-Pakistan

*Corresponding author email address: ctsabe_sgr@hotmail.com



(Received, 10th February 2022, Revised 18th September 2022, Published 20th September 2022)

Abstract: Human hand is highly evolved in terms of complexity and variations. In this modern medical era, vascular anatomy of the human hand has clinical importance in medical, surgical and radiological sciences. The intention of the current study is to determine the variations which occur as the radial artery branches thus making a contribution to the arterial supply of the index finger and the thumb. The study design was descriptive case series, carried out in the Department of Anatomy in King Edward Medical University from December 2018 to May 2019 on 30 cadaveric limbs. Vivisection of the cadaveric hands was performed following Cunningham's Manual of practical anatomy. The origin and the course of RA, UA and MA were dissected and identified with further exploration of the blood supply of the index finger and the thumb. All details were entered in a predesigned proforma, and the dissected limbs were photographed. Data was analyzed to find the frequencies of superficial palmar arch as well as the arterial supply of thumb and index finger were also expressed in frequencies. Great variation was observed in the arterial supply to palmar aspect of index finger and thumb. Main contributing artery being radial artery in majority of cases through its common palmar or proper palmar branches arising from SPA or SPBRA. Ulnar artery and median artery were also observed to be supplying these areas in 6.6% and 3.3% cases respectively. The median artery when present was replacing the radial artery on palmar aspect of hand. The dorsum, however, was supplied by the princeps pollicis and the radialis indicis branches of radial artery in all the cases. We concluded that in about 1/3rd (11/30 are incomplete SPA) of our studied sample, arterial supply of the index finger and the thumb is highly dependent on radial artery and should any damage occur to it, vitality of these useful structures will be compromised.

Keywords: SPA, Radial artery, Median artery, Ulnar artery, Palmar aponeurosis

Introduction

The awareness of the diversifications in vascular framework of the hand is very helpful to the surgeons, for the microsurgical operations done for the amputations and in crush injuries of the hand. The usefulness of collateral blood flow of the hand is vital for the radial artery harvest in for coronary bypass grafting (Nair *et al.*, 2013; Starnes *et al.*, 1999). Diversifications in the development of superficial palmar arch are common. In addition to diversity in superficial palmar arch, there is also diversification in branches of the radial artery supplying the superficial palmar arch and arterial supply of the index finger and the thumb (Bianchi, 2001; Gellmann *et al.*, 2001; Madhyastha *et al.*, 2011). Allen's and modified Allen's test, Color doppler ultrasonography, Upper limb arteriography, oxygen saturation by pulse oximeter can accordingly be opted in order to appraise the effectiveness of collateral arterial flow prior to surgical interventions. Radial artery is one of the bifurcations of arteria brachialis; other one being the arteria ulnaris,

branched off in the ante cubital fossa. In its course, arteria radialis sends off several branches at forearm, as well as wrist and the hand. Main branches of radial artery in the hands are princeps pollicis artery and radialis indicis artery. Radial artery then continues as deep palmar arch by anastomosing with the deep palmar branch from the ulnar artery (Salgado *et al.*, 2014; Moore and Dally, 1999; Standring, 2005). The princeps pollicis and the radialis indices arteries are responsible mainly in the arterial supply of the index finger and thumb at the dorsal aspect of the human hand. However, arterial supply on palmar aspect is quite variable. Usually, the superficial palmar arch gets completed by any of three branches from the arteria radialis i.e., superficial palmar branch (SPBRA), radialis indicis artery (RIA) or princeps pollicis artery (PPA) (Salgado *et al.*, 2014; Earlet, 1986; Erbil *et al.*, 1999). The contribution of all these arteries in the arterial supply has been reported to be very variable in the studies conducted so far. Contribution from median artery in completion of SPA and blood supply of hand has also been reported (Bataineh *et al.*, 2009).

[Citation: Inam, T., Tafweez, R., Bukhari, Z.H., Khalid, W. (2022). Anatomical variations in arterial supply of thumb and index finger in cadaveric hands. *Biol. Clin. Sci. Res. J.*, 2022: 100. doi: <https://doi.org/10.54112/bcsrj.v2022i1.100>]

Similarly, contribution from ulnar artery is very variable, in addition to completing SPA, it has been reported to supply thumb as well (Maj *et al.* 1973; Showri and Senthil, 2016; Suman and Jayanthi. 2011; Bilge *et al.*, 2006). Keeping in mind the blood supply of thumb in clinical settings, the existence of extensive variations, the present study was designed to explore these details in our population.

Methodology

A descriptive study was carried out in the Department of Anatomy of King Edward Medical University from December 2018 to May 2019. Cadavers available for academic and research purposes in the Anatomy Department of KEMU were included, excluding the limbs on which dissection was not possible due to damage or severe contracture of the hand. Dissection of the cadaveric hands was performed following Cunningham's Manual of practical anatomy (Romanes, 2005). The dissection was done to explore the RA, UA and MA and the origin of the branches supplying the thumb and the index finger were further explored. Magnifying lens was used where required. All details were entered in a pre-designed proforma, and the dissected limbs were photographed. Data regarding the arterial supply of index finger and thumb was analyzed and expressed in frequencies.

Results

A total of 30 cadaveric hands, 17 right and 13 left, were dissected. In all of these hands, radialis indicis artery was seen emerging from radial artery for supply to the dorsum of index finger. Princeps pollicis artery was also identified in all hands, arising from radial artery and supplying dorsal aspect of thumb (Fig-1). However, the supply to palmar aspect of thumb and index finger showed many variations. The index finger was supplied by proper digital artery at radial aspect and common digital arteries at ulnar aspect, but the origin of these

digital arteries was very variable. The proper digital artery originated from SPA in 10/30 (33.3%) cases (Fig-2) while in 3 hands it was emerging from SPBRA. Similarly, common digital artery was originating from SPA in 5 hands and SPBRA in 2 hands (Fig-3) Rather unexpected finding was emergence of proper digital artery to radial aspect of the index finger in 2 hands (Fig-4) In these instances, the superficial palmar arch was not formed and the sole supply to palmar aspect of hand was mainly coming from ulnar artery (Table-1). Similarly, in one hand common digital artery was seen to be emerging from median artery (Fig-5). In this case the median artery was also supplying the palmar surface of the thumb and radial aspect of index finger through a common digital branch. Superficial palmar arch was again incomplete in this case as well and main supply to hand was coming from ulnar and median arteries. As regards the arterial supply to palmar aspect of thumb, great variation was again noticed. A proper digital artery for supply to thumb was noted in 11/30 (36.67%) hands. It was originating from SPA in 8 hands (Fig-2) and from SPBRA in 3 hands. A common digital artery for supply to index finger and thumb was seen in 7 hands. In majority (5 hands, 71.43%) it was arising from SPA and in 2 (28.57%) hands it was coming from SPBRA (Fig-3; Table-2)

In the hand where median artery was seen contributing in supply to hand, a common digital artery was visible emerging from median artery for supply to adjacent sides of index finger & thumb (Fig-5). It is important to note that in 7 hands no separate branch for supply to palmar aspect of index finger could be identified, meaning by that the blood was coming from arteria radialis indicis only (branch of radial artery). Similarly, in 11 hands a branch other than princeps pollicis could not be identified as additional supply to palmar aspect of thumb, therefore, the sole supply to thumb was from radial artery alone in these cases.

Table-1: Arterial Supply of the Index Finger

Contributing Branch	N	%
Proper Digital Branch of SPA	10/30	33.33%
Common Digital from SPA	5/30	16.67%
Proper Digital from SPBRA	3/30	10%
Common Digital from SPBRA	2/30	6.67%
Common Digital from Median Artery	1/30	3.33%
Proper Digital from Ulnar Artery	2/30	6.67%
Radialis Indicis Only	7/30	23.33%

Table-2: Arterial Supply of the Thumb

Contributing Branches	N	%
Proper Digital from SPA	8/30	26.67%
Common Digital from SPA	5/30	16.67%
Proper Digital from SPBRA	3/30	10%
Common Digital from SPBRA	2/30	6.67%
Common Digital from Median Artery	1/30	3.33%
Princeps Pollicis Only	11/30	36.67%

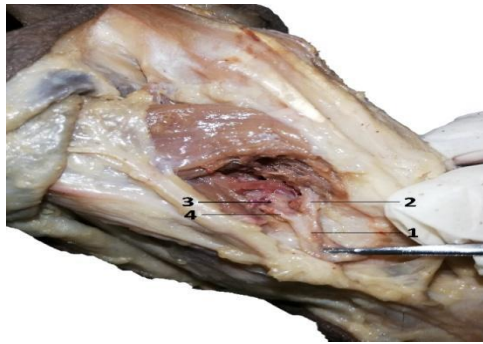

Figure-1: Branches of Radial Artery at the Dorsal surface of the Left Hand. 1-Arteria Radialis. 2-Princeps Pollicis Artery. 3-Deep Branch of Radial Artery. 4-Radialis Indicis Artery

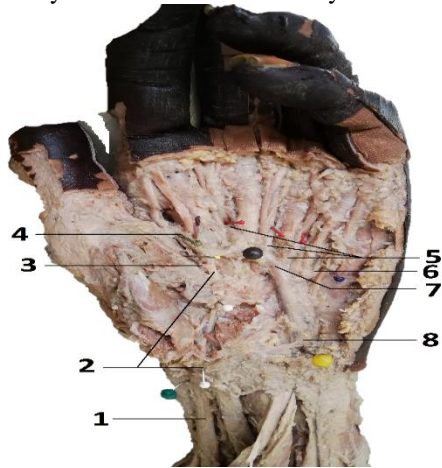


Figure-2: Left Hand. 1- Arteria Radialis. 2-SPBRA. 3-Proper Digital Artery to the Thumb. 4-Proper Digital Artery to Index Finger. 5-Common Digital Arteries of SPA. 6-Proper Digital Artery to Little Finger. 7-Complete SPA. 8-Ulnar Artery

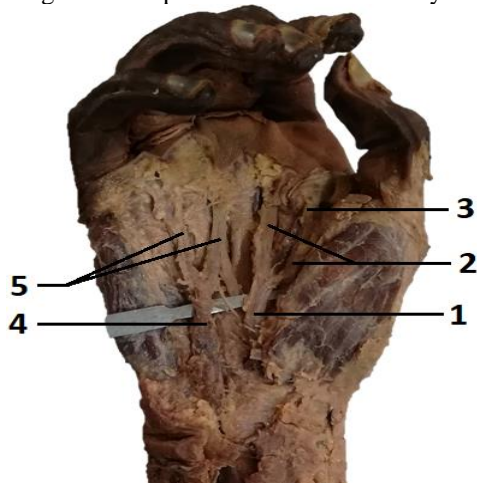


Figure-3: Right Hand. 1-SPBRA of Radial Artery. 2- Common Digital Arteries from SPBRA. 3- Proper

Digital Artery to the Index Finger. 4- Arteria Ulnaris. 5-Common Digital Arteries from Ulnar Artery

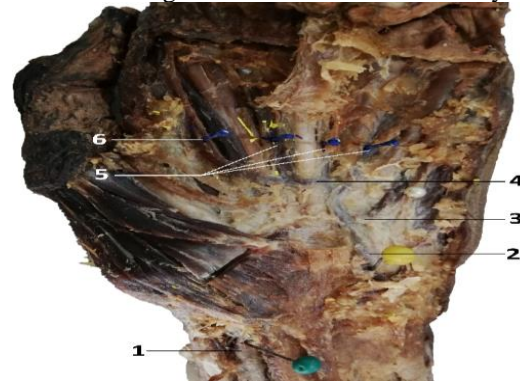


Figure-4: Left Hand. 1-Radial Artery. 2-Ulnar Artery to the Little Finger. 3-Proper Digital Artery to the Little Finger. 4-Incomplete SPA. 5-Common Digital Arteries from Ulnar Artery. 6-Proper Digital Artery to the Index Finger

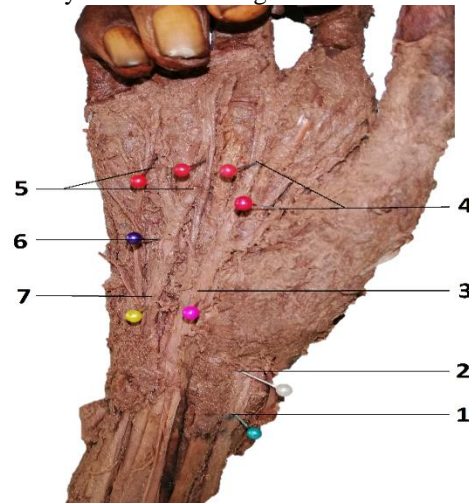


Figure-5: Right Hand. 1-Radial artery. 2-SPBRA. 3-Median artery, 4-Common Digital Arteries from the Median Artery. 5-Common Digital Arteries from the Ulnar Artery. 6-Proper Digital Artery to the Little Finger. 7-Ulnar Artery

Discussion

As far as the detailed description of digital blood supply by common and / or proper digital arteries is concerned our study is unique in providing additional information about variations observed according to contribution from ulnar, radial and median arteries. The median artery was observed in 6.67% (2/30) of the hands in our study. In one hand it was completing the SPA whereas in the other hand, median artery gave two common digital arteries supplying the thumb, two sides of the index finger and lateral

[Citation: Inam, T., Tafweez, R., Bukhari, Z.H., Khalid, W. (2022). Anatomical variations in arterial supply of thumb and index finger in cadaveric hands. *Biol. Clin. Sci. Res. J.*, 2022: 100. doi: <https://doi.org/10.54112/bcsrj.v2022i1.100>]

aspect of the middle finger. In other words, it was replacing the radial artery. This observation highlights the truth that the major source of the vascular supply to index and middle finger is very variable. As the origin of superficial palmar arch is considered important, it is the determination of the contribution from the radial artery to the arch and to the fingers which are considered of greater significance as radial artery is harvested and it is the conduit of choice in CABG procedure as a bypass graft now a days. The contribution of radial artery was more frequently seen in right hands with complete SPA, 66.67% (8/12) as well as in incomplete SPA, 60% (3/5). This fact should be borne in mind while conducting commonly done procedures like angiography through the right radial artery.

The extent to which arteria radialis and arteria ulnaris contribute to the arterial flow of the hand can easily be measured via an array of invasive as well as non-invasive techniques together with Allen's test, ultrasonography and angiography (Pola *et al.*, 1996). Although Allen's test has become quite obsolete now but the alternate methods like ultrasonography and angiography must be employed before performing any such procedure. When the arteria radialis was explored at the dorsal aspect of the hand, the distribution was consistent in all the cases under study. It was seen to be divided into arteria radialis indicis to give blood supply to the index finger, arteria princeps pollicis supplying the thumb and deep branch of the radial artery to make deep palmar arch. Although arteria radialis indicis and arteria princeps pollicis were present in all the dissected hands, additional supply of the index finger and the thumb on the palmar aspect showed considerable variability. In case of complete SPA, the medial aspect of index finger had arterial supply from SPA whatever the source of SPA was. However, the radial aspect of the index finger had arterial supply from SPA (Fig-2) in 79% (15/19) hands. The rest of the hands did not have any additional supply on palmar aspect. However, the picture was different in cases with the incomplete SPA where SPBRA provided blood supply to the radial aspect of index finger in (Fig-3) 45% (5/11) hands, median artery (Fig-4) in 9% (1/11) and ulnar artery (Fig-5) in 18% (2/11)

hands. These results reflect that blood flow to the radial aspect of index finger is highly variable. Although princeps pollicis arising from arteria radialis was supplying the dorsum of thumb, the arterial contribution to the thumb, as regards to the palmar aspect, was also very variable. In case of complete SPA, in 68% (13/19) hands a branch from SPA (Fig-2) was supplying the palmar aspect of the thumb. In incomplete SPA, 45% (5/11) of the dissected hands showed that arterial contribution to the thumb was taken from SPBRA (Fig-3) and in 9% (1/11) by the median artery (Fig-4). In the rest of the cases arteria princeps pollicis remained the only supply.

Salgado *et al* (2014) conducted a study on 25 cadaveric hands in Srilanka, reported an arterial pattern different from our study. They noted that radial aspect of the thumb had arterial contribution from the princeps pollicis artery in only 20% and SPBRA in 80% of the dissected hands. Whereas the ulnar aspect of the thumb had arterial contribution by SPA in 44% cases and by princeps pollicis artery in 32% of the thumbs. Keeping in mind the results of present study, it is quite evident that great variation exists in arterial vasculature in the hand. In cases of trauma to the wrist or hand compromising the blood supply, elective surgical procedures like RA harvesting, plastic surgical reconstruction etc. the most vulnerable area is the radial aspect of index finger as well as the thumb. In case of incomplete SPA, such risk is further augmented. It thus becomes imperative to make the medical personnel and especially the surgical team aware of the existence of such extensive variations in this functional vital part of the body. This study revealed that incomplete SPA is not an uncommon occurrence since we observed it in 36.67% (11/30) cases. But the description of this type of blood supply to hand is lacking in most of the textbooks of anatomy. It would not be harsh to comment that the description of blood supply of hand remains incomplete without mention of existence of these variations. Ours is the only study conducted in Pakistan and due to limited availability of the cadavers, the sample size was also kept minimum. Conduction of many such studies in different parts of the country is the need of time in order to provide a sound guideline for surgeons.

[Citation: Inam, T., Tafweez, R., Bukhari, Z.H., Khalid, W. (2022). Anatomical variations in arterial supply of thumb and index finger in cadaveric hands. *Biol. Clin. Sci. Res. J.*, 2022: 100. doi: <https://doi.org/10.54112/bcsrj.v2022i1.100>]

Conclusion

- Arterial supply to dorsum of hand does not show variation.
- Great variation is present in blood supply to ventral aspect, especially index finger and thumb thus making these areas most vulnerable to ischemic damage.
- Contribution of arteries in supply to index finger is
 - Radial Artery 63.33%, Ulnar artery 56.67% and Median artery 6.67%
 - SPA in 50% and incomplete SPA 26.67%
- Contribution of arteries in supply to thumb is
 - Radial Artery 56.67%, Ulnar artery 43.33%, Median artery 6.67%
 - SPA in 43.33% and incomplete SPA 20%

In case of any trauma or elective surgical procedures on the hand, especially index finger and thumb, it is important to consider and evaluate their arterial supply to ensure ischemia and necrosis free events, hence, preventing permanent damage to these vital functioning structures of the human body. Further similar studies are recommended to be carried out in different parts of the country to consolidate the data of our population as a guideline for surgeons.

Conflict of interest

The authors have proclaimed that there is no conflict of interest.

References

- Bataineh, Z. M., Habbal, O., & Moqattash, S. T. (2009). Variations in the superficial palmar arch of the hand. *Italian Journal of Anatomy and Embryology= Archivio Italiano di Anatomia ed Embriologia*, **114**(1), 11-20.
- Bianchi, H. (2001). Anatomy of the radial branches of the palmar arch. Variations and surgical importance. *Hand clinics*, **17**(1), 139-46.
- Bilge, O., Pinar, Y., Özer, M. A., & Gövsa, F. (2006). A morphometric study on the superficial palmar arch of the hand. *Surgical and Radiologic Anatomy*, **28**(4), 343-350.
- Earley, M. J. (1986). The arterial supply of the thumb, first web and index finger and its

surgical application. *The Journal of Hand Surgery: British & European*, **11**(2), 163-174.

- Erbil, M., Aktekin, M. U. S. T. A. F. A., Denk, C. C., Önderoglu, S., & Sürücü, H. S. (1999). Arteries of the thumb originating from the superficial palmar arch: five cases. *Surgical and Radiologic Anatomy*, **21**(3), 217-220.
- Gellman, H., Botte, M. J., Shankwiler, J., & Gelberman, R. H. (2001). Arterial patterns of the deep and superficial palmar arches. *Clinical Orthopaedics and Related Research®*, **383**, 41-46.
- Madhyastha, S., Murlimanju, B. V., Jiji, P. J., Saralaya, V. V., Rai, A., & Vadgaonkar, R. (2011). Morphological variants of the human superficial palmar arch and their clinical implications. *Journal of Morphological Science*, **28**(4), 261-264.
- Moore LK, Dally AF. Clinically oriented anatomy. 7th edition. *Williams and Wilkins; Philadelphia, Lippincott*. 1999; p 757-82.
- Pola, P., Serricchio, M., Flore, R., Manasse, E., Favuzzi, A., & Possati, G. F. (1996). Safe removal of the radial artery for myocardial revascularization: a Doppler study to prevent ischemic complications to the hand. *The Journal of Thoracic and Cardiovascular Surgery*, **112**(3), 737-744.
- Nair, C. K. V., Nair, R. V., Mookambica, R. V., Somayaji, S. N., Somayaji, K., & Jetty, R. (2013). An anatomical variation of Superficial Palmar Arch and its clinical significance: A Case Report. *Anatomy Journal of Africa*, **2**(1), 114-116.
- Romanes, GJ. Cunningham's manual of practical anatomy. 15th edition. *Oxford: Oxford university press*. 2005. Vol. 1, p. 74-104.
- Salgado, L. S. S., Hasan, R., AAMMSL, P., Wijesundara, W. M. R. D., & Anuradha, W. K. (2014). Variations of the superficial palmar arch in a sri Lankan perspective: A cadaveric study. *GSTF Journal of Advances in Medical Research (JAMR)*, **1**(2): (2):61-70.
- Showri R, Senthil KS (2016). A study on ulnar dominant complete superficial palmar arch. *Internatioanl Journal of Anatomy Research*. **4**(3):2587-9.

[Citation: Inam, T., Tafweez, R., Bukhari, Z.H., Khalid, W. (2022). Anatomical variations in arterial supply of thumb and index finger in cadaveric hands. *Biol. Clin. Sci. Res. J.*, **2022**: 100. doi: <https://doi.org/10.54112/bcsrj.v2022i1.100>]

- Standring S. Grey's Anatomy. 39th edition. In Wrist and Hand. Elsevier Churchill livingstone. Edition London (UK); 2005; p1549-51.
- Standring S. Grey's Anatomy. 39th edition. In Wrist and Hand. Elsevier Churchill livingstone. Edition London (UK); 2005; p1616-20.
- Starnes, S. L., Wolk, S. W., Lampman, R. M., Shanley, C. J., Prager, R. L., Kong, B. K., ... & Whitehouse Jr, W. M. (1999). Noninvasive evaluation of hand circulation before radial artery harvest for coronary artery bypass grafting. *The Journal of Thoracic and Cardiovascular Surgery*, **117**(2), 261-266.
- Suman, U., & Jayanthi, K. S. (2011). A study of complete superficial palmar arches formed entirely by ulnar artery. *Journal of Anatomical Society of India*, **60**(2), 199-201.



Open Access This article is licensed under a Creative Commons Attribution 4.0 International License, which permits use, sharing, adaptation, distribution and reproduction in any medium or format, as long as you give appropriate credit to the original author(s) and the source, provide a link to the Creative Commons licence, and indicate if changes were made. The images or other third party material in this article are included in the article's Creative Commons licence, unless indicated otherwise in a credit line to the material. If material is not included in the article's Creative Commons licence and your intended use is not permitted by statutory regulation or exceeds the permitted use, you will need to obtain permission directly from the copyright holder. To view a copy of this licence, visit <http://creativecommons.org/licenses/by/4.0/>.

© The Author(s) 2022