

ASSESSMENT OF INCIDENCE OF PULMONARY EMBOLISM IN COVID-19 PATIENTS: A SINGLE-CENTER STUDY

RANA MA^{*1}, SIDDIQI MRO², SIDDIQUI MH³, RAZA A⁴, AWAD AHA⁵, ABDELBAKY AM⁵, ELMASRY WG⁵, HANIF S⁶

¹*Department of Critical Care Medicine, Amna Inayat Medical College & Bahria International Hospital, Lahore, Pakistan*

²*Department of Cardiology, United Medical and Dental College, Karachi, Pakistan*

³*Department of Medicine, Akhtar Saeed Medical and Dental College, Lahore, Pakistan*

⁴*Department of Radiology, Bahria International Hospital, Lahore, Pakistan*

⁵*Department of Intensive Care Medicine, Rashid Hospital, Dubai, United Arab Emirates*

⁶*Department of Medicine, Expert Doctor Private Limited, Lahore, Pakistan*

*Correspondence author email address: drasimrana@yahoo.com

(Received, 12th October 2022, Revised 26th January 2023, Published 18th March 2023)

Abstract: *Pulmonary embolism (PE) is a life-threatening disease with a high death toll. Recent research has shown that patients with COVID-19 are more likely to experience PE because of the inflammatory reaction and hypercoagulability. This article's goal is to assess the prevalence of PE among hospitalized COVID-19 patients. We examined the medical files of 210 individuals hospitalized in the COVID-19 unit at Bahria Town International Hospital Lahore between September 1, 2020, and September 30, 2021. Real-time polymerase chain reaction was used to identify COVID-19 in the patients and computed tomography pulmonary angiography (CTPA) was performed to ascertain PE. Of the 210 patients, 9 experienced PE, constituting a 4.3% incidence rate in our study. Our research demonstrates that PE frequently occurs in COVID-19 hospitalized patients. Based on the results, it can be concluded that preventive measures should be considered for people with COVID-19 disease, especially those with a smoking history and low oxygen levels. The fatality rates linked to this illness can be decreased by early diagnosis and timely treatment.*

Keywords: COVID-19, pulmonary embolism, hypercoagulability, endothelial dysfunction, venous thromboembolism

Introduction

COVID-19 is a pandemic caused by the severe acute respiratory syndrome coronavirus 2 (SARS-CoV-2), which first emerged in Wuhan, China, in December 2019 (Kamel Boulos and Geraghty, 2020). The disease has affected millions worldwide, leading to severe illness and death in some cases. Among the many complications of COVID-19, pulmonary embolism (PE) is a significant one that can be fatal if not diagnosed and treated promptly (Sakr et al., 2020). The evidence that connects COVID-19 to pulmonary embolism (PE), a condition that can be fatal and is characterized by the obstruction of one or more pulmonary arteries in the lungs, continues to increase (Remy-Jardin et al., 2021). PE is characterized by the inability of blood to flow through the lungs. Clots of blood can form in the deep veins of the legs or in other parts of the body that connect to the lungs, which can lead to pulmonary embolism (PE). The coronavirus family produces multiple strains of the COVID-19 virus (Khanna et al., 2022). This virus can range in

severity from mild to severe, and it can cause organ failure or even death. Patients with COVID-19 have an increased risk of developing various complications, with PE being one of the most dangerous. Studies have observed the occurrence of blood clots in hospitalized COVID-19 patients (Priyadarshini et al., 2020). This is significant because PE is associated with high mortality rates and is a leading cause of death in COVID-19 patients. Patients with COVID-19 are at an increased risk for thrombotic complications, such as arterial and venous thrombosis, with poor expectations of patient outcomes (Li et al., 2021). Patients who have COVID-19 have a higher risk of getting thrombosis for a number of reasons, some of which include endothelial dysfunction, platelet inactivation, stagnant blood flow, and an intensified inflammatory response. The levels of D-dimer can be utilized as a predictor of thrombotic risk in COVID-19 patients. COVID-19 patients have an increased risk of thrombosis, an



important consideration (Spyropoulos et al., 2020). However, very few published data are available regarding PE in COVID-19 patients being treated in hospitals (Cantador et al., 2020). As a direct result of this, the primary objective of this research is to investigate the extent to which this group is affected by PE. This study aimed to investigate the incidence of PE in COVID-19 patients and analyze the clinical features and imaging findings of PE in COVID-19 patients.

Methodology

A total of 210 records of confirmed cases of COVID-19 infection on RT-PCR were included in the study from September 2020 to September 2021. This study was conducted at the Bahria Town International Hospital Lahore after the approval of the hospital's institutional review board and ethical committee. Pulmonary embolism (PE) was identified using computed tomography angiography (CPTA). Patients with clinically diagnosed COVID-19 were enrolled, and chest CTs were done on those who showed clinical signs of pulmonary embolism. Patients who had non-enhanced chest CTs were removed from the study. A Contrast Enhanced CT scan with PE protocol was used for image analysis (pulmonary CT angiography). Without being aware of the patient's clinical or biological conditions, two chest radiologists

examined the patient's chest CT scan patterns and PE status. Multiple readings were taken in some cases. SPSS version 24 was used to conduct statistical analysis. Clinical factors associated with PE were evaluated based on the size of CT lesions. The student t-test was used to compare categorical and continuous data, respectively. The threshold for significance was fixed at P 0.05.

Results

210 hospitalized patients, fulfilling the initial recruiting criteria, were analyzed. The mean age of the participants was 52.5 ± 9.2 years, with 48% male population. Among these patients, 201 had unenhanced chest CT because of no suspicion of PE. Nine patients with severe clinical symptoms of COVID-19 and refractory hypoxia were studied using enhanced material-contrast CT (Figure 1). PE was found in 9 individuals in a total of 210 patients, representing an incidence rate of 4.3% among COVID-19 hospitalized patients. The 5 patients were females, and 4 were males. The Chi-Square analysis showed no significant difference in the incidence of PE among the genders ($p > 0.05$). Although these patients were moved to the critical care unit, it turned out that the patients with severe diseases had increased their respiratory rate, and oxygen saturation was less than 92%.

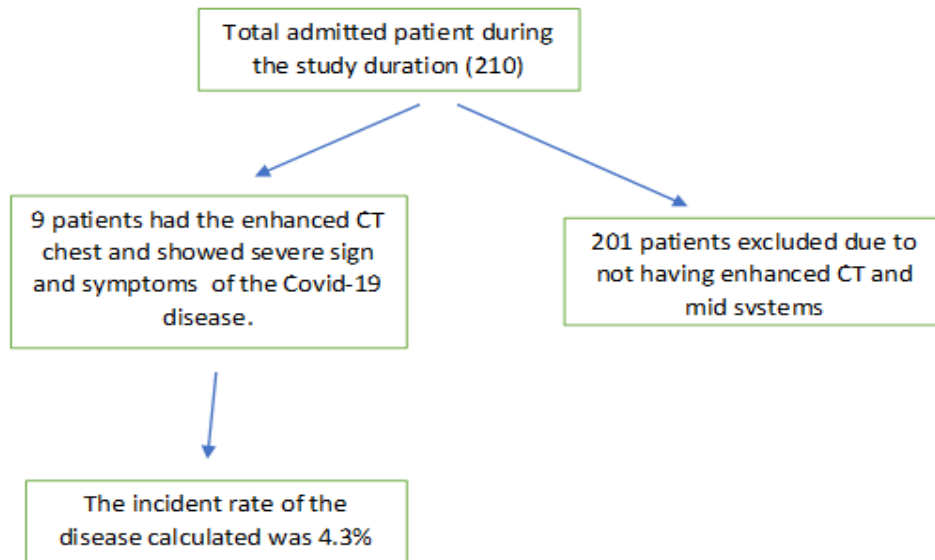


Figure 2 shows the incidence of PE in COVID-19 patients.

Discussion

According to the results of this study, 4.3 percent of hospitalized COVID-19 patients had an incidence of

PE, which is similar to the findings of other studies. According to a Zhang et al. study from 2020, patients with COVID-19 had a PE incidence of 3.7% (Dai et

[Citation: Rana M.A., Siddiqi M.R.O., Siddiqui M.H, Raza A., Awad A.H.A., Abdelbaky A.M., Elmasry W.G, Hanif S (2023). Assessment of incidence of pulmonary embolism in covid-19 patients: a single-center study. *Biol. Clin. Sci. Res. J.*, 2023: 230. doi: <https://doi.org/10.54112/bcsrj.v2023i1.230>]

al., 2020). The incidence of PE in COVID-19 patients was estimated to be 7.7 percent in a later study by Lodigiani et al. (2020) (Lodigiani et al., 2020). The incidence varies among studies; however, these studies indicate that COVID-19 patients have an elevated chance of having PE.

The incidence of PE among the genders in this study did not show any discernible variation. This result aligns with some studies' findings, which showed no difference in PE incidence between the sexes among COVID-19 patients. For instance, Lodigiani et al. (2020) discovered no discernible variation in the incidence of PE between males and females (Lodigiani et al., 2020). However, several research studies have noted a higher frequency of PE in men than in women. PE was observed to occur more frequently in males than in females in research by Huang et al. (2020). It is unclear why there is a gender gap, and more research is needed to determine the cause (Evans et al., 2021).

Contrast-enhanced computed tomography (CECT) was used in this investigation to examine patients with severe clinical COVID-19 symptoms (KHAN et al., 2022). These patients were shown to have lower oxygen saturation and a higher respiratory rate, which are characteristics of COVID-19. These results imply that PE in COVID-19 patients can be challenging to identify since the underlying COVID-19 condition might hide the PE symptoms (Mejia et al., 2020). Therefore, clinicians should understand the potential for PE in COVID-19 individuals, especially those with significant clinical symptoms.

Kanne, J. P. et al. identified using unenhanced chest CT (Kanne et al., 2021). For patients with severe clinical COVID-19 symptoms, contrast CT was employed. Individuals with COVID-19 exhibit similar PE imaging findings to patients without COVID-19. The imaging results of PE in this investigation were consistent with those described in other studies, including filling deficiencies, vessel wall thickening, and distal pulmonary artery dilatation. In some situations, it might be difficult to diagnose PE because the imaging results may be unusual or faint (D'Armini, 2015). Because of this, doctors should be mindful of the limits of imaging in the diagnosis of PE and should combine clinical and imaging evidence to arrive at a firm diagnosis.

When analyzing the study's findings, it's essential to consider its limitations. A modest sample size of 210 hospitalized COVID-19 patients served as the study's initial testing population. In light of this, it's possible that the results cannot be applied to the larger group of COVID-19 patients. Second, because only one center was used for the study, there may be fewer circumstances in which the results can be applied. Third, the lack of a control group in the study made it difficult to compare the incidence of PE in COVID-19 patients to non-COVID-19 patients. A control

group might have made this comparison easier. Fourth, the study omitted information that would have been crucial to the treatment and prognosis of PE in COVID-19 patients, such as details about the exact therapies used and the results of the patients who had it.

Conclusion

The study found that the incidence of pulmonary embolism (PE) in hospitalized COVID-19 patients was 4.3%, with no significant gender difference. Clinicians should be aware of the possibility of PE in COVID-19 patients, especially in those with severe clinical symptoms. Early diagnosis and prompt treatment of PE in COVID-19 patients are crucial to prevent fatal outcomes. Further research is needed to better understand the underlying mechanisms of PE in COVID-19 patients and to develop effective prevention and treatment strategies.

Conflict of interest

The authors declared an absence of conflict of interest.

References

- Cantador, E., Núñez, A., Sobrino, P., Espejo, V., Fabia, L., Vela, L., de Benito, L., and Botas, J. (2020). Incidence and consequences of systemic arterial thrombotic events in COVID-19 patients. *Journal of thrombosis and thrombolysis* 50, 543-547.
- D'Armini, A. M. (2015). Diagnostic advances and opportunities in chronic thromboembolic pulmonary hypertension. *European Respiratory Review* 24, 253-262.
- Dai, M., Liu, D., Liu, M., Zhou, F., Li, G., Chen, Z., Zhang, Z., You, H., Wu, M., and Zheng, Q. (2020). Patients with cancer appear more vulnerable to SARS-CoV-2: A multicenter study during the COVID-19 outbreak. *Cancer discovery* 10, 783-791.
- Evans, S., Alkan, E., Bhangoo, J. K., Tenenbaum, H., and Ng-Knight, T. (2021). Effects of the COVID-19 lockdown on mental health, wellbeing, sleep, and alcohol use in a UK student sample. *Psychiatry research* 298, 113819.
- Kamel Boulos, M. N., and Geraghty, E. M. (2020). Geographical tracking and mapping of coronavirus disease COVID-19/severe acute respiratory syndrome coronavirus 2 (SARS-CoV-2) epidemic and associated events around the world: how 21st century GIS technologies are supporting the global fight against

- outbreaks and epidemics. Vol. 19, pp. 1-12. Springer.
- Kanne, J. P., Bai, H., Bernheim, A., Chung, M., Haramati, L. B., Kallmes, D. F., Little, B. P., Rubin, G., and Sverzellati, N. (2021). COVID-19 imaging: what we know now and what remains unknown. *Radiology* 299, E262-E279.
- KHAN, M. N., KHAN, S. B., Khan, S., Zainab, S., Khokhar, A., and Kamran, A. (2022). Incidence of Pulmonary Embolism in Covid-19 Patients. *Pakistan Journal of Medical and Health Sciences*, 891-893.
- Khanna, N. N., Maindarkar, M., Puvvula, A., Paul, S., Bhagawati, M., Ahluwalia, P., Ruzsa, Z., Sharma, A., Munjral, S., and Kolluri, R. (2022). Vascular Implications of COVID-19: Role of Radiological Imaging, Artificial Intelligence, and Tissue Characterization: A Special Report. *Journal of Cardiovascular Development and Disease* 9, 268.
- Li, P., Zhao, W., Kaatz, S., Latack, K., Schultz, L., and Poisson, L. (2021). Factors associated with risk of postdischarge thrombosis in patients with COVID-19. *JAMA network open* 4, e2135397-e2135397.
- Lodigiani, C., Iapichino, G., Carenzo, L., Cecconi, M., Ferrazzi, P., Sebastian, T., Kucher, N., Studt, J.-D., Sacco, C., and Bertuzzi, A. (2020). Venous and arterial thromboembolic complications in COVID-19 patients admitted to an academic hospital in Milan, Italy. *Thrombosis research* 191, 9-14.
- Mejia, F., Medina, C., Cornejo, E., Morello, E., Vásquez, S., Alave, J., Schwalb, A., and Málaga, G. (2020). Oxygen saturation as a predictor of mortality in hospitalized adult patients with COVID-19 in a public hospital in Lima, Peru. *PloS one* 15, e0244171.
- Priyadarshini, I., Mohanty, P., Kumar, R., Son, L. H., Chau, H. T. M., Nhu, V.-H., Thi Ngo, P. T., and Tien Bui, D. (2020). Analysis of outbreak and global impacts of the COVID-19. In "Healthcare", Vol. 8, pp. 148. MDPI.
- Remy-Jardin, M., Duthoit, L., Perez, T., Felloni, P., Faivre, J.-B., Fry, S., Bautin, N., Chenivresse, C., Remy, J., and Duhamel, A. (2021). Assessment of pulmonary arterial circulation 3 months after hospitalization for SARS-CoV-2 pneumonia: dual-energy CT (DECT) angiographic study in 55 patients. *EclinicalMedicine* 34, 100778.
- Sakr, Y., Giovini, M., Leone, M., Pizzilli, G., Kortgen, A., Bauer, M., Tonetti, T., Duclos, G., Zieleskiewicz, L., and Buschbeck, S. (2020). Pulmonary embolism in patients with coronavirus disease-2019 (COVID-19) pneumonia: a narrative review. *Annals of intensive care* 10, 1-13.
- Spyropoulos, A. C., Levy, J. H., Ageno, W., Connors, J. M., Hunt, B. J., Iba, T., Levi, M., Samama, C. M., Thachil, J., and Giannis, D. (2020). Scientific and standardization committee communication: clinical guidance on the diagnosis, prevention, and treatment of venous thromboembolism in hospitalized patients with COVID-19. *Journal of Thrombosis and Haemostasis* 18, 1859-1865.



Open Access This article is licensed under a Creative Commons Attribution 4.0 International License, which permits use, sharing, adaptation, distribution and reproduction in any medium or format, as long as you give appropriate credit to the original author(s) and the source, provide a link to the Creative Commons licence, and indicate if changes were made. The images or other third party material in this article are included in the article's Creative Commons licence, unless indicated otherwise in a credit line to the material. If material is not included in the article's Creative Commons licence and your intended use is not permitted by statutory regulation or exceeds the permitted use, you will need to obtain permission directly from the copyright holder. To view a copy of this licence, visit <http://creativecommons.org/licenses/by/4.0/>.
© The Author(s) 2023